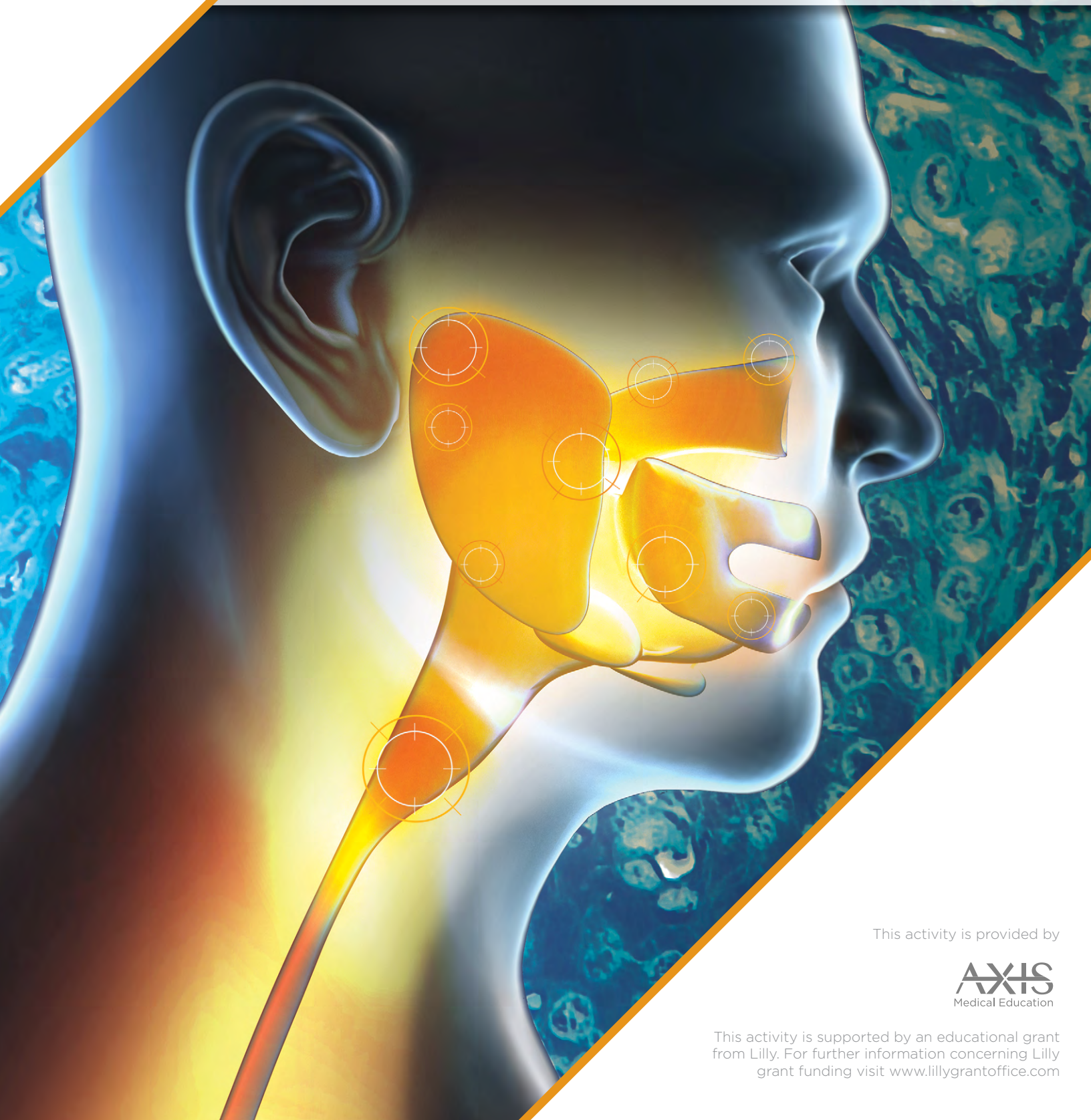


Understanding Treatment Strategies for Squamous Cell Carcinoma of the Head and Neck

This transcript has been edited for style and clarity and
includes all slides from the presentation.



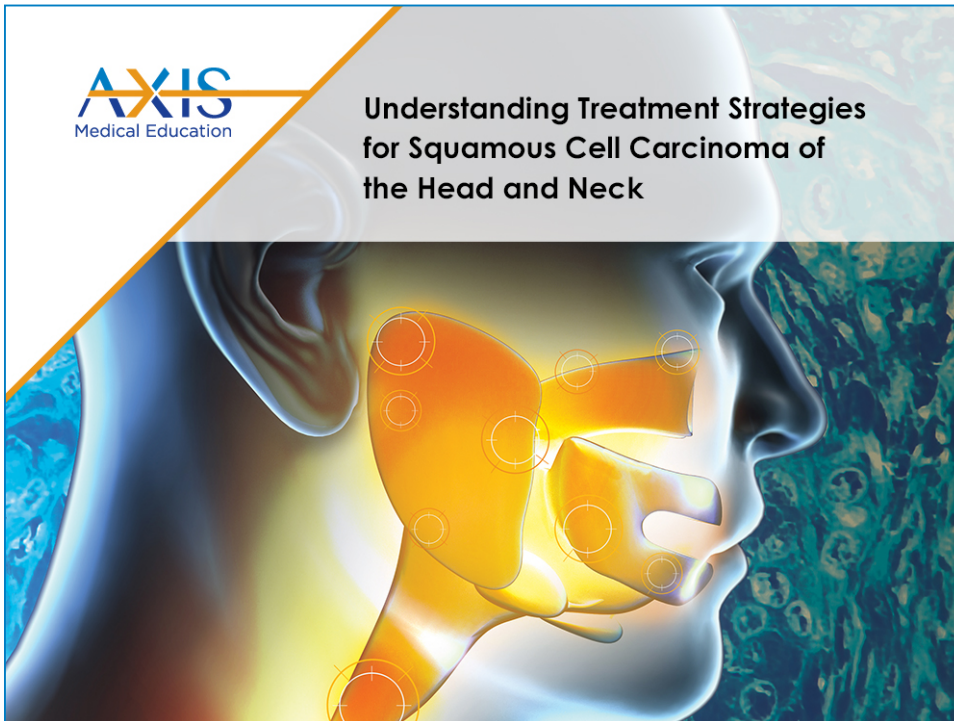
This activity is provided by

AXIS
Medical Education


This activity is supported by an educational grant
from Lilly. For further information concerning Lilly
grant funding visit www.lillygrantoffice.com

Understanding Treatment Strategies for Squamous Cell Carcinoma of the Head and Neck

Robert L. Ferris, MD, PhD



- ▶ Robert L. Ferris, MD, PhD: Welcome to this educational activity "Understanding Treatment Strategies for Squamous Cell Carcinoma of the Head and Neck."



Robert L. Ferris, MD, PhD

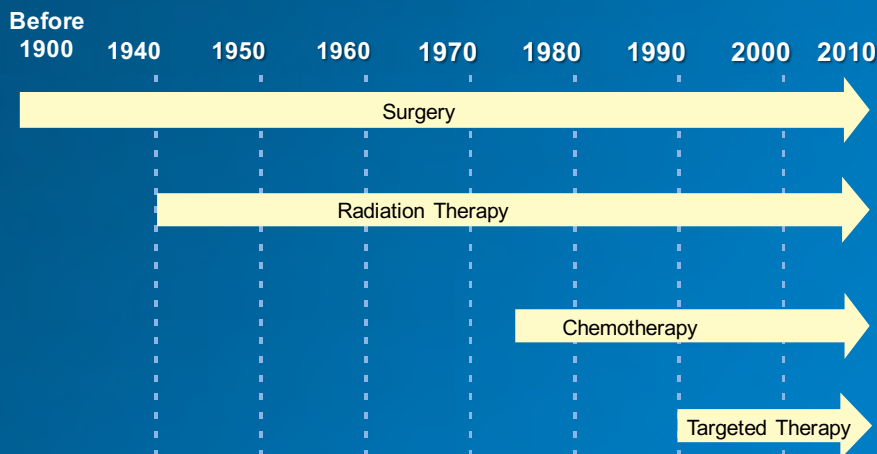
UPMC Endowed Professor and Vice-Chair
Chief, Division of Head and Neck Surgery
Associate Director for Translational Research
Co-Leader, Cancer Immunology Program
University of Pittsburgh Cancer Institute
Pittsburgh, Pennsylvania

- ▶ I'm Dr. Robert Ferris, UPMC Endowed Professor and Vice Chair, Chief of the Division of Head and Neck Surgery, Associate Director for Translational Research, and Co-Leader of the Cancer Immunology Program at the University of Pittsburgh Cancer Institute in Pittsburgh, Pennsylvania.

Molecular and Biological Considerations for Squamous Cell Carcinoma of the Head and Neck

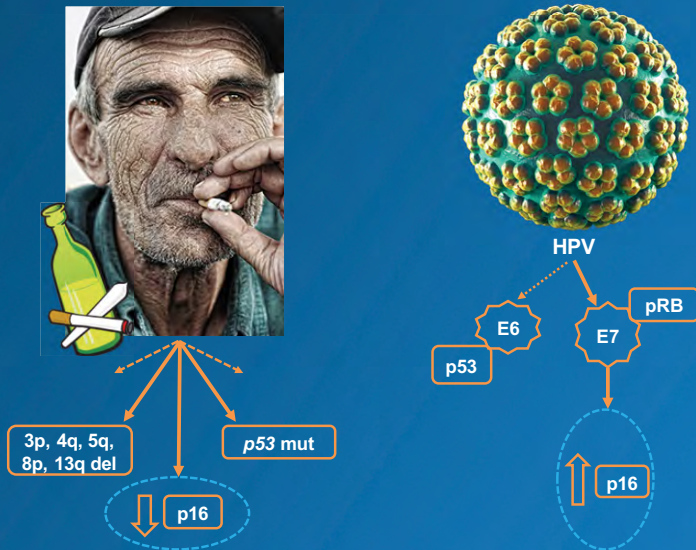
- So let's begin. First, I'll discuss molecular and biological considerations for squamous cell carcinoma of the head and neck.

Evolution of Treatment for Head and Neck Cancer



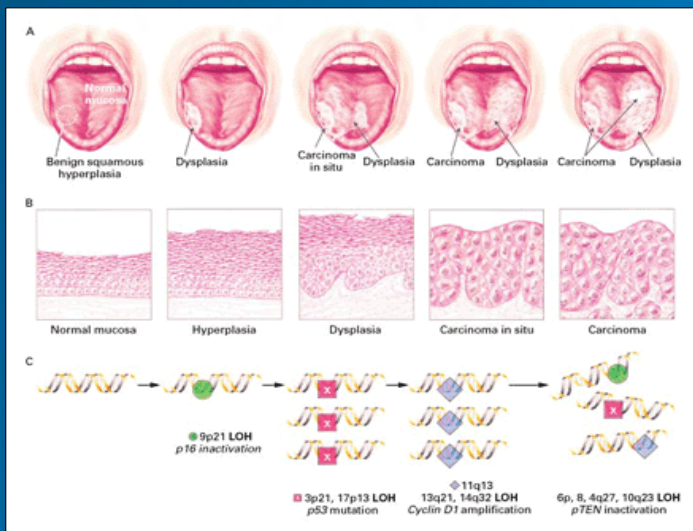
- For years, surgery, radiation, and chemotherapy were the conventional modalities that have been used to try to cure as many patients with head and neck cancer as possible. We developed a better understanding of the biology of tumor cells and their interaction with the host in the patient. This has led to targeted therapy addressing these advances in biology in ways that can target the tumor or the immune system in a way that is much more selective and hopefully has less side effects and toxicity than the conventional modalities of surgery, radiation, and chemotherapy.

Two Distinct Diseases Comprise HNC



- More importantly, the precise impact of the treatment implications is important since we now are aware that 2 distinct diseases comprise head and neck squamous cell carcinoma: tobacco carcinogen-exposed cancers (as shown on the left) with a number of mutations in tumor suppressors and genomic instability; and (on the right) human papillomavirus (HPV)-associated head and neck cancers, which are characterized by oncogenes transforming the cell and leading to invasion and metastasis.

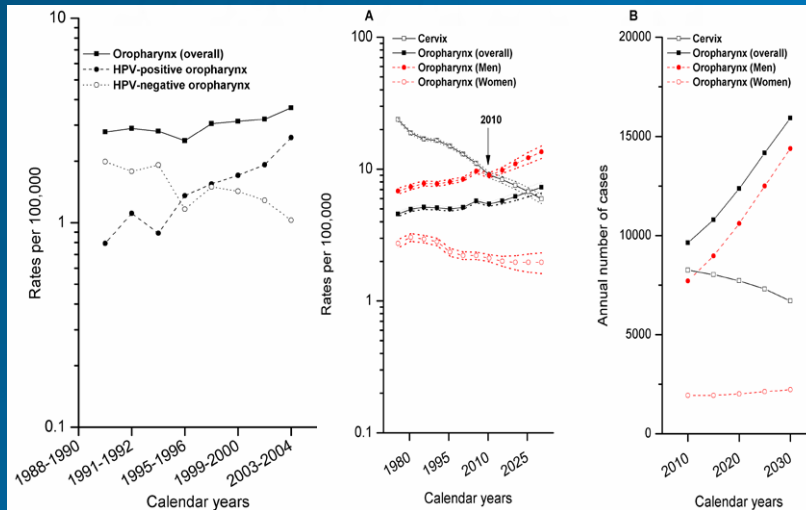
Head and Neck Cancer Disease Progression



- Head and neck cancer disease progression occurs in a sequential accumulation of mutations and inactivation of tumor suppressors, which leads to invasiveness, metastasis, and treatment resistance.

Califano et al, *Cancer Res.* 1996;56:2488-2492; Forastiere et al, *N Engl J Med.* 2001;345:1890-1900.

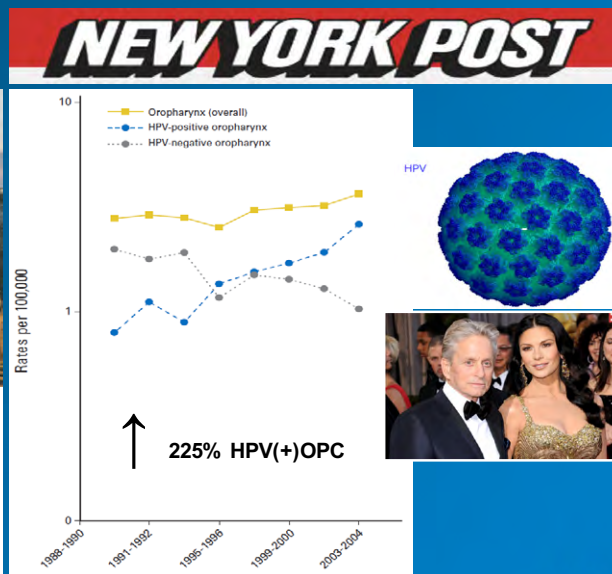
Change in HPV Rates and Incidence Over Time: United States



Chaturvedi et al, *J Clin Oncol*. 2011;29:4294-4301.

AXIS
Medical Education

- Interestingly, effects on smoking cessation have led to a decrease in carcinogen—or smoking-induced cancers—and there's been an increase in HPV-associated cancers. This incidence is approximately 250% over the past 2 to 3 decades or a 5% increase per year every year for the past 20 to 30 years, as shown in this slide.



OPC, oropharyngeal cancer.
Centers for Disease Control and Prevention; Chaturvedi et al, *J Clin Oncol*. 2011;29:4294-4301.

AXIS
Medical Education

- Interestingly, the increase in HPV-associated cancers is now approaching the annual incidence of cervical cancers, and it's become a very dominant HPV-associated cancer in the United States, and so it's a major clinical health problem and is distinguished from the head and neck cancers caused by tobacco-associated exposures. This has an important implication for treatment.

RTOG 0129

Survival Estimates, Causes of Death, and Patterns of Treatment Failure in Patients with Oropharyngeal Cancer, According to Tumor HPV Status			
Variable	HPV-Positive (n = 206)	HPV-Negative (N = 117)	P Value†
OS at 3 years, % (95% CI)	82.4 (77.2-87.6)	57.1 (48.1-66.1)	<0.001
Cause of death, no. of patients/total no. (%)			
Primary cancer	25/50 (50.0)	29/58 (50.0)	
Second primary tumor	4/50 (8.0)	8/58 (13.8)	
Protocol treatment	1/50 (2.0)	0/58	
Nonprotocol treatment	1/50 (2.0)	1/58 (1.7)	
Cause unrelated to cancer or treatment	10/50 (20.0)	8/58 (13.8)	
Unknown	9/50 (18.0)	12/58 (20.7)	
PFS at 3 years, % (95% CI)	73.7 (67.7-79.8)	43.4 (34.4-52.4)	<0.001
Local-regional relapse at 3 years, % (95% CI)	13.6 (8.9-18.3)	35.1 (26.4-43.8)	<0.001
Distant metastasis at 3 years, % (95% CI)	8.7 (4.9-12.6)	14.6 (8.1-21.1)	0.23

➤ HPV-negative OPC = High RISK
 Overall survival: ⬇ 25.1% reduction
 PFS: ⬇ 30.3% reduction
 Local-regional relapse: ⬆ 21% increase
 DM: ⬆ 5.9 % increase (n.s.)

HPV, human papillomavirus; OS, overall survival; PFS, progression-free survival.

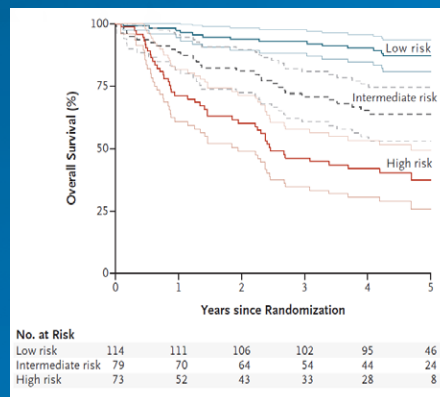
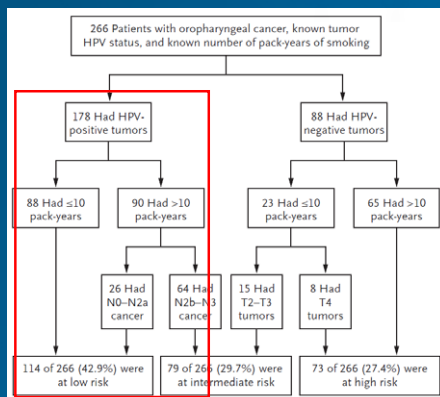
†P values were calculated with the use of Gray's test, except for overall and progression-free survival, for which the log-rank test was used, and cause of death, for which Pearson's chi-square test was used. The P value for the cause of death was calculated with primary cancer, protocol treatment, and nonprotocol treatment combined.

Ang et al. *N Engl J Med.* 2010;363:24-35.

AXIS
Medical Education

➤ The largest study to correlate clinical outcome based on HPV status was the Radiation Therapy Oncology Group 0129 study. This was a study that compared different fractionation schemes of radiation therapy. The overall endpoint was not necessarily important for the purposes of this talk. The important thing is to recognize that this provided a large cohort of patients with well annotated clinical outcome so that we could demonstrate and observe that the progression-free and overall survival are dramatically better in the HPV-associated or HPV-positive head and neck cancers versus the HPV-negative with a net improvement of 20% to 30% overall survival in the HPV-positive cancers.

HPV Status and Survival in RTOG 0129



3-year OS 93.0% (95% CI 88.3-97.7) in the low-risk group,
 70.8% (95% CI 60.7-80.8) in the intermediate-risk group

HPV, human papillomavirus; OS, overall survival.
 Ang et al. *N Engl J Med.* 2010;363:24-35.

AXIS
Medical Education

➤ This study also was large enough that other prognostic biomarkers such as tobacco smoking and tumor burden could be used to segregate the patients into low risk, intermediate risk, and high risk. As we'll discuss later, the low-risk patients are potentially candidates for clinical trials of de-intensified therapy. The high-risk patients need to be intensified with additional types of treatments, and we'll get into this later.

Distinct Molecular and Biological HNC Types

HPV-Related Cancers

- Caused by high-risk HPV
 - HPV 16
 - Driven by viral oncogenes
- Restricted to oropharynx
- Distinct molecular markers
- “Good” prognosis
- Young, good general health

Environment-Related Cancers

- Caused by environmental mutagens (smoking, alcohol)
- Throughout oral mucosa
- Distinct molecular markers
- “Poor” prognosis, comorbidity
- Second cancers

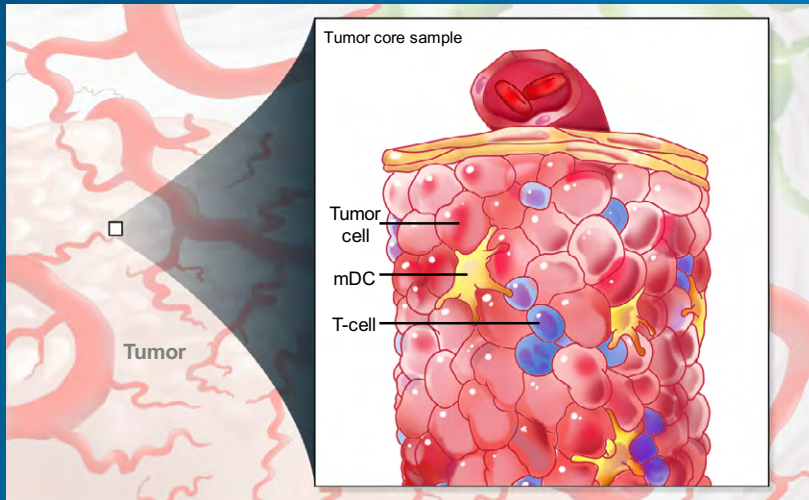
HPV, human papillomavirus.
The Cancer Genome Atlas Network, *Nature* 2015;517:576-582.

AXIS
Medical Education

► It's important to understand that there are distinct molecular and biological subtypes beyond the overview, as I've given, of HPV-related or environmental carcinogen-related cancers. HPV-related cancers are caused by, for the most part, high-risk type 16 HPV subtype. The cancers are driven by the viral oncogenes. Interestingly, the HPV-driven cancers are primarily restricted to the oropharynx, which is composed of the tonsil and the base of the tongue. There are distinct molecular markers, in particular, high overexpression of the protein p16. We've already discussed that they have a better prognosis, and these patients are younger and generally have fewer comorbidities.

The environment- or carcinogen-related cancers are caused by mutagens such as smoking and heavy alcohol use. They have a field cancerization throughout the oral mucosa. There are distinct molecular markers, a worse prognosis, and higher rate of comorbidity, and second primary cancers in the upper aerodigestive tract at a rate of 2% to 3% per year every year of a second or a third primary cancer. So these clinical characteristics are mirrored by different biological and molecular features.

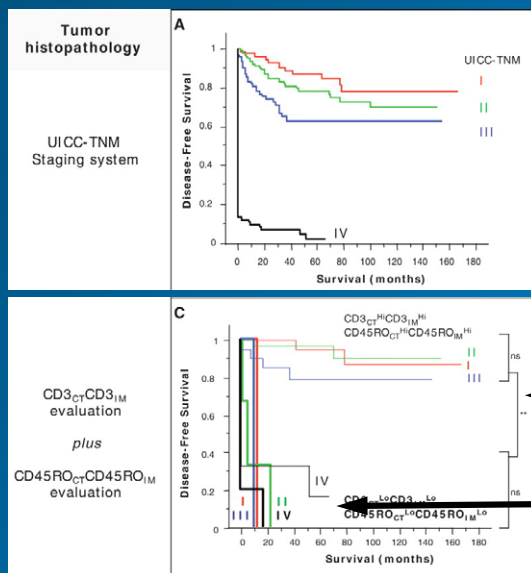
Immune Cells Exist Within the Tumor Microenvironment



AXIS
Medical Education

- It's also important to recognize that immune cells exist within the tumor microenvironment. The tumor is not only composed of tumor cells, but also there are infiltrating inflammatory cells, some of them activating, others suppressive; there are stromal macrophages and fibroblasts. We'll discuss some of these. However, it's important to understand that there is heterogeneity in that these immune cells are important biomarkers of clinical outcome.

Importance of Immunity on Tumor Prognosis



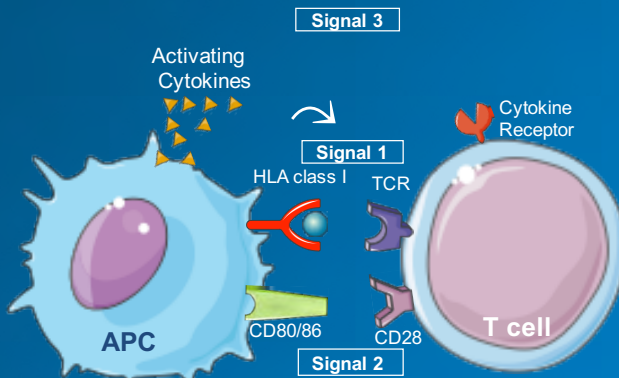
TIL, tumor-infiltrating lymphocytes.
Galon et al. *Science* 2006;313:1960-1964.

AXIS
Medical Education

- The next slide demonstrates the impact of immunity on tumor prognosis. One can see on the bottom that, stage-for-stage, the higher density of tumor-infiltrating lymphocytes confer a better prognosis. Even early stage cancers with infrequent or low-density tumor-infiltrating lymphocytes have a poor prognosis. So the goal of targeted immunotherapy is to increase the tumor-infiltrating lymphocytes and attempt to confer a better prognosis by stimulating immunity against the patient's cancer.

Normal T Cell Activation: Signals 1, 2, and 3

All 3 signals are required to mount a proper immune response



Immune System activation

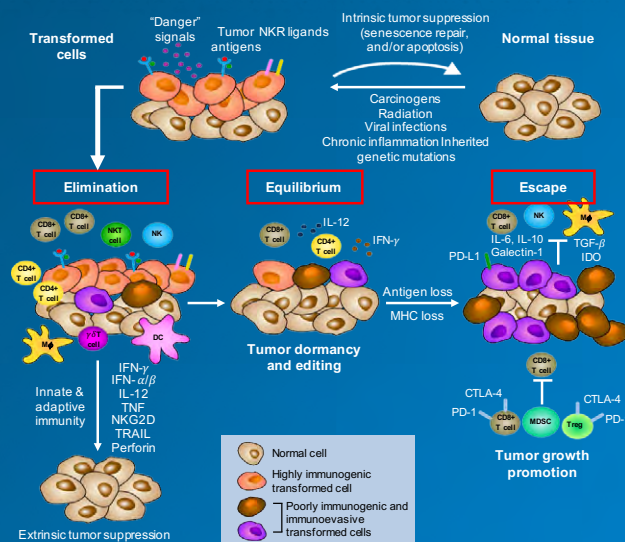
Adapted from Gutmacher and Becher, *J Clin Invest*. 2007;117:1119-1127.

AXIS
Medical Education

- We need to understand some of the normal activation signals of the immune system that are required to mount a proper immune response; these are the goals of immunotherapy against cancer. Signal 1 is the T-cell receptor recognizing its ligand, the HLA and antigen peptide complex. Signal 2 is called co-stimulation, and it's necessary for a full activation. There can be co-inhibitory signal 2s, which inactivate the T cells and turn them off. Signal 3 is a shaping or modulating step, mainly mediated by cytokines and other inflammatory signals. This shapes and modifies the duration, the durability, and the differentiation of the particular T-cell immune response.

Cancer Immunoediting: Elimination → Equilibrium → Escape

Tumor cells with a less immunogenic phenotype escape immune surveillance and induce a tolerant microenvironment



Adapted from Schreiber et al. *Science* 2011;331:1565-1570.

AXIS
Medical Education

- Important to immunotherapy is understanding that cancers are exposed to the immune system for a long time—months or years—prior to the development of symptoms. So, there is a series of steps in which the immune system interacts with the tumor cell.

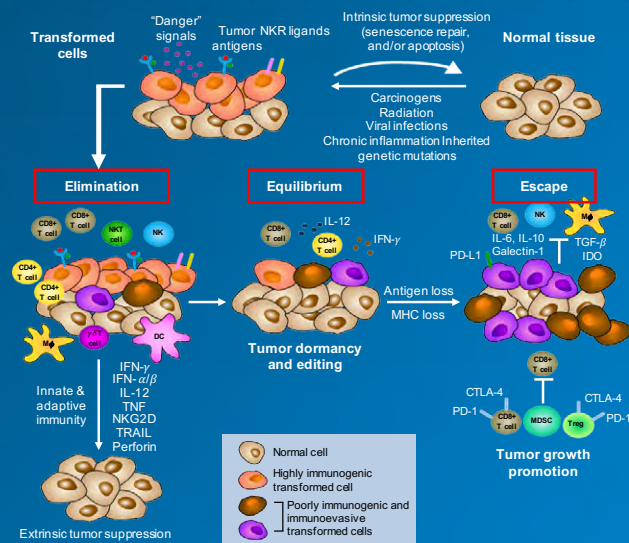
The first step is the elimination phase, where many of us are exposed to premalignant cells, and our immune system removes those premalignant cells by recognizing them as abnormal.

The second step is the equilibrium step, which lasts for months or years. The immune system interacts with the premalignant cell as it is progressing, accumulating other genetic changes, or being infected by a progressing viral infection.

(cont'd on next page)

Cancer Immunoediting: Elimination → Equilibrium → Escape

Tumor cells with a less immunogenic phenotype escape immune surveillance and induce a tolerant microenvironment



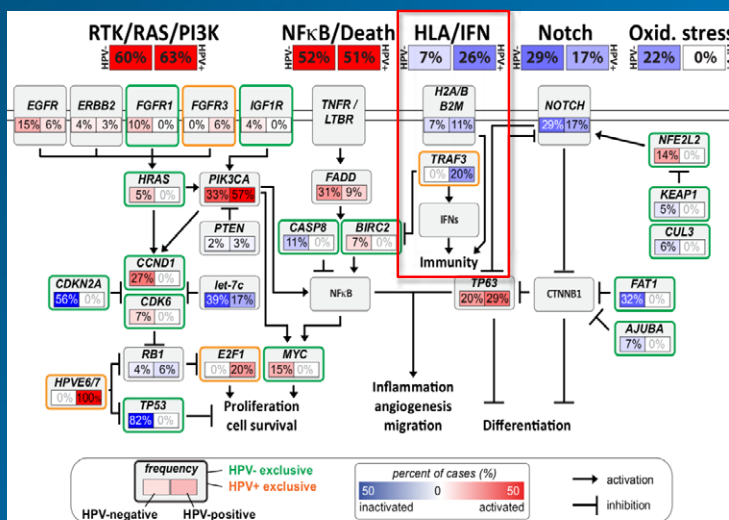
Adapted from Schreiber et al. *Science* 2011;331:1565-1570.

AXIS
Medical Education

(cont'd from previous page)

Finally, the third step is the escape phase where the tumor cell escapes and evades the immune system. The upregulation of various suppressive cell types and markers occur within the tumor microenvironment. These can be targetable. However, the escape phase is characterized by the development of symptoms such as pain or bleeding or pressure on important structures. This leads the patient to the physician. The goal of immunotherapy is to turn the clock back, reactive the immune system, and overcome immune escape to re-implement or establish the elimination phase turning the clock back.

Mutational Landscape of Head and Neck Cancer: Implications for Immunotherapy

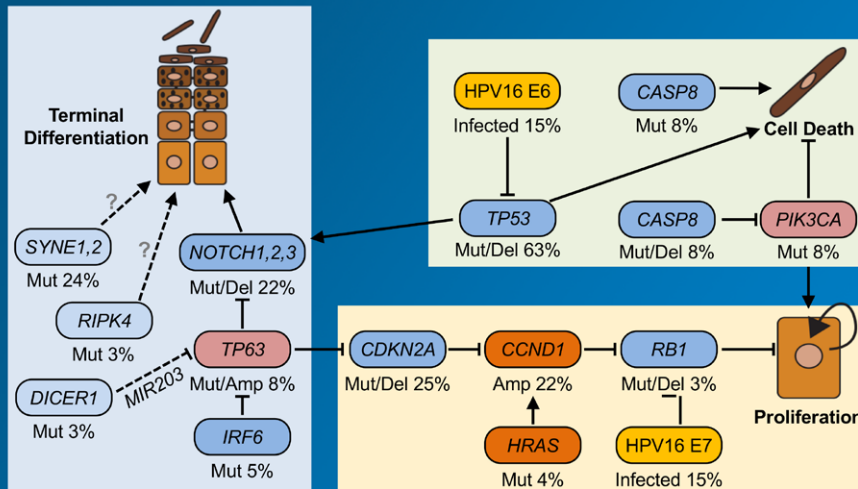


The Cancer Genome Atlas Network. *Nature* 2015;517:576-582.

AXIS
Medical Education

- Interestingly, the immune escape hypothesis was demonstrated to have some evidence in favor of it with the publication of The Cancer Genome Atlas, the so-called mutational landscape of head and neck cancer. And as you can see in the red box, there are baseline mutations or inactivating changes in the HLA and the interferon pathway, which indicate that the immune escape progression and the cancer immunoediting that we discussed on the prior slide is, in fact, important since this leads to inactivation through different mutations. Also, this would potentially be a barrier of immunotherapy. We need to recognize that patients may come to the physician already with mutations in the HLA or interferon pathway and may have some difficulty with immunotherapy turning on the inflammatory process again.

Signaling Pathways in Head and Neck Cancer



Adapted from Stransky et al. *Science* 2011;333:1157-1160.

AXIS
Medical Education

- There are a number of signaling pathways that have been identified through the mutational landscape. These are potentially targetable, as well. The NOTCH 1, 2, and 3 pathways have been identified. We also see inactivating mutations in CDKN2A and other cyclin-dependent kinases responsible for cellular turnover and proliferation. There are alterations activating mutations in the PI3 kinase pathway, which can prevent tumor cell death and lead to proliferation. So, these activating mutations lead to inappropriate proliferation and activation of different metabolic pathways associated with signaling in head and neck cancer cells.

Significantly Mutated Genes in HNSCC by Whole Exome Sequencing

Analysis – Juok Cho, Peter Hammerman, Carrie Sougnez

Commonly mutated genes in SCCHN

<i>TP53</i>	(tumor suppressorgene, p53)
<i>CDKN2A</i>	(cyclin dependent kinase inhibitor, p16)
<i>FAT1</i>	(cellular polarization, tumor suppressor)
<i>PIK3CA</i>	(oncogenic signal transduction pathway)
<i>NOTCH1</i>	(transmembrane cellular fate determinant)
<i>MLL2</i>	(histone methyltransferase)
<i>NSD1</i>	(transcription coregulator protein)

What is that to oncologists?
No *ALK*, No *ROS*,
No *EGFR*, No *KRAS*

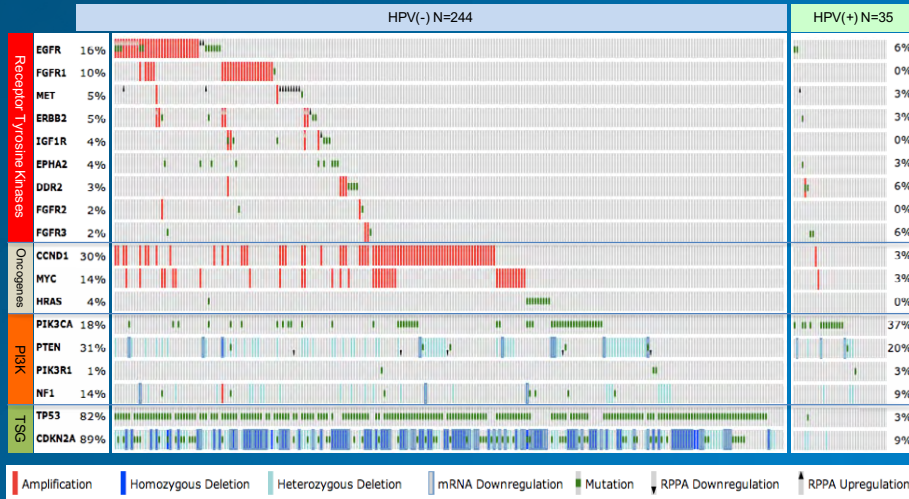
HNSCC, head and neck squamous cell cancer.
The Cancer Genome Atlas Network. *Nature* 2015;517:576-582.

AXIS
Medical Education

- Whole exome sequencing has also demonstrated that a number of these mutations are not only present but may be targetable. Unfortunately, the large majority of alterations are in tumor suppressor proteins. So these can be difficult to target. They may activate a large number of downstream pathways. But, unlike some other cancers, like lung cancer, there are no smoking gun oncogenes that can be targeted with different small molecule therapeutics. And so, in the absence of driver mutations in head and neck cancer, we recognize that targeting particular alterations may be challenging. So it's important to keep in mind that we don't have some of these activating mutations in *EGFR* or *ALK* or *KRAS*, which can be targeted in other cancer types.

Candidate Therapeutic Targets

Analysis – Tanguy Seiwert, Niki Schultz

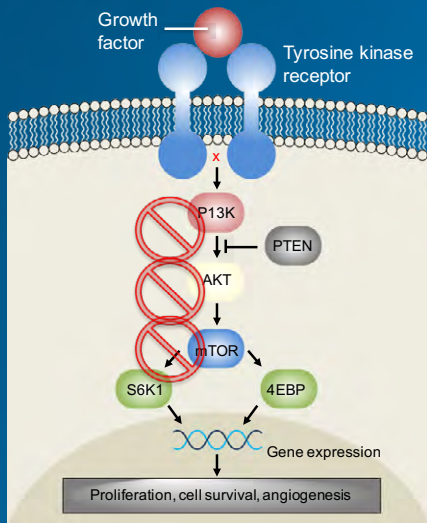


► In The Cancer Genome Atlas paper, however, we can see that some of these mutations are present. There is either an activating mutation or overexpression through a copy number increase. Some of these are selective to HPV-positive versus HPV-negative cells. In particular, the PI3 kinase-activating mutations are more commonly seen in the HPV-positive tumors. The p53 alterations or inactivating of the tumor suppressor p53 are much more common in the HPV-negative cancers.

The Cancer Genome Atlas Network. *Nature* 2015;517:576-582.

AXIS
Medical Education

PI3K Pathway Inhibitors Are Here



PI3K/AKT inhibitors are here

CAL101
PX-866
IPI-145
BAY 80-6946 (in early stage clinical)
BEZ235
RP6503
TGR 1202
SF1126
INK1117
GDC-0941
BKM120
XL147
XL765
Palomid
ZSTK474
PWT33597

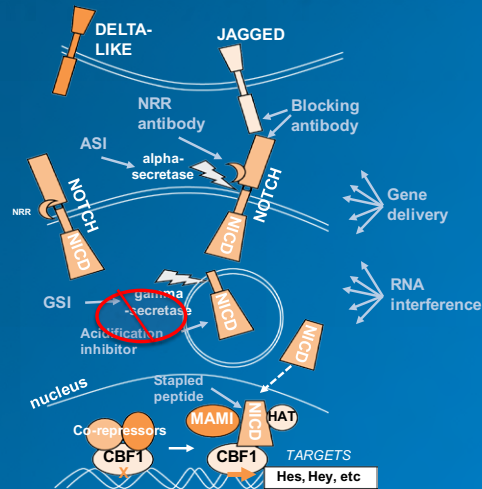
And there are mTOR inhibitors too!
everolimus (0/9 responders in unselected pts)
temsirolimus

► *PI3* is a commonly altered gene. I mentioned this is more common in HPV-positive cancers. It's about two-fold higher. So, 15% to 20% in the HPV-negative cancers and 30% to 40% in the HPV-positive cancers. One can see that these activating mutations can be targeted by a long list of PI3 kinase inhibitors. There are different PI3 kinase subunits, and these can be targeted with selective inhibitors. The PI3 kinase-activating mutations activate the mTOR pathway. And so, potentially everolimus and temsirolimus mTOR inhibitors can actually be used to inhibit pathways in cancers where the *PI3* gene is activated.

mTOR, mechanistic target of rapamycin; PI3K, phosphoinositide 3-kinase; PTEN, phosphatase and tensin homolog. Adapted from Holmes. *Nat Rev Drug Discov.* 2011;10:563-564.

AXIS
Medical Education

NOTCH Pathway Targeting: Gamma Secretase Inhibitors Are in the Clinic Now But NOTCH Underexpressed, Not Overexpressed



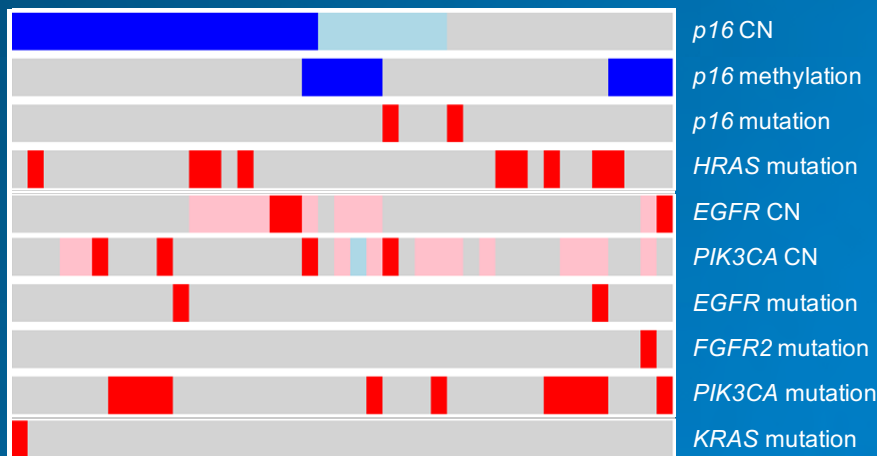
ASI, alpha-secretase inhibitor; GSI, gamma-secretase inhibitor; HAT, histone acetyl-transferase; MAML, mastermind-like; NICD, notch intracellular domain; NPR, negative regulatory region.
Adapted from Purow. *Adv Exp Med Biol.* 2012;727:305-319.

AXIS
Medical Education

- The NOTCH pathway was identified in The Cancer Genome Atlas. These are targeted by gamma-secretase inhibitors; these are also in the clinic. Interestingly, these are overexpressed, and so we need to inhibit this effect.

High Rate of Oncogene Activation in p53 Wild-Type Disease (60%)

Analysis – Ni Zhao, Vonn Walter, Matt Wilkerson



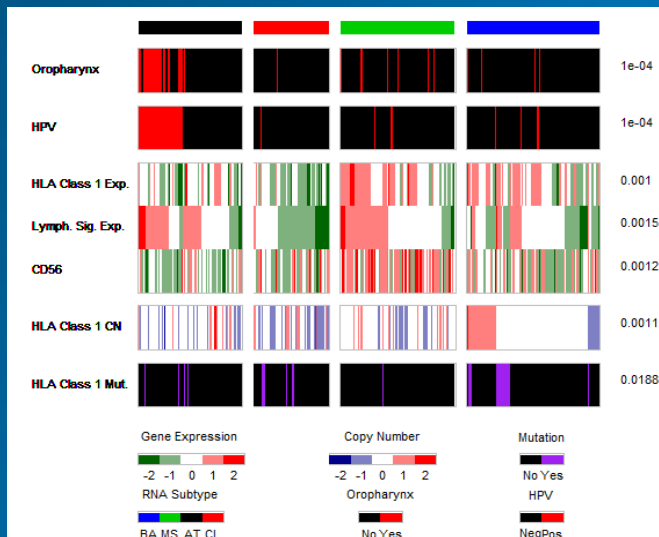
The Cancer Genome Atlas Network. *Nature* 2015;517:576-582.

AXIS
Medical Education

- I mentioned that the most common activation of mutations in head and neck cancer is through p53. However, in a number of wild-type p53 tumors, there are other downstream targetable alterations that may be important therapeutically as small molecules are developed.

Differential Immune Signature by Expression Subtype

Analysis – Vonn Walter, Bob Ferris



The Cancer Genome Atlas Network. *Nature* 2015;517:576-582.

AXIS
Medical Education

- The Cancer Genome Atlas also demonstrated that there is a differential immune signature. This allows characterization and classification of different subsites, as might be expected in the oropharynx where HPV is present, there is a unique immune expression signature. In particular, this may help us to understand responses to immunotherapy as we get into that later.

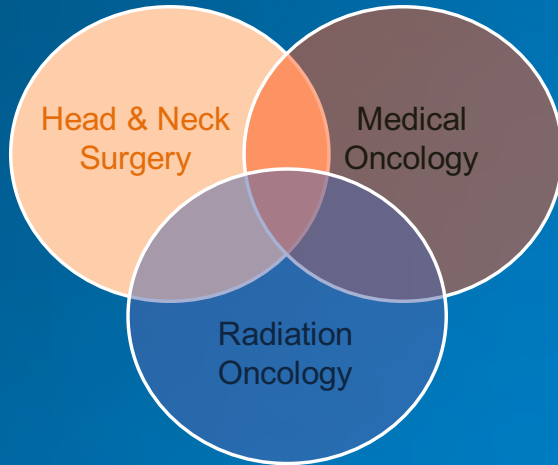
AXIS

Multidisciplinary and Survivorship Considerations

- Now I'm going to discuss multidisciplinary and survivorship considerations.

Multidisciplinary Management of Head and Neck Cancer

Collaboration for a Common Goal



AXIS
Medical Education

► It's important to recognize that head and neck cancer affects important structures and physiology of speaking, breathing, and swallowing. Although the patient often starts with the head and neck surgeon for diagnosis and the most accurate staging, there is a multidisciplinary team that's required because there are multiple modalities, and collaboration is key. Multidisciplinary discussion and management is key since often patients are treated with multiple different modalities at different phases of their treatment, and it's important for the different clinicians with complementary expertise to be involved early on in the treatment paradigm.

Multidisciplinary Team

Multidisciplinary Team

- Head and neck surgery
- Radiation oncology
- Medical oncology
- Plastic and reconstructive surgery
- Specialized nursing care
- Dentistry/prosthodontics
- Physical medicine and rehabilitation
- Speech and swallowing therapy
- Clinical social work
- Nutrition support
- Pathology (including cytopathology)
- Diagnostic radiology
- Adjunctive services (eg, neurology, ophthalmology, psychiatry, addiction services, audiology, palliative care)

Support Services

- General medical care
- Pain and symptom management (see NCCN Guidelines for Adult Cancer Pain)
- Nutritional support (eg, enteral feeding, oral supplements)
- Dental care for radiation therapy (RT) effects
- Xerostomia management
- Smoking and alcohol cessation
- Speech and swallowing therapy
- Audiology
- Tracheotomy care
- Wound management
- Depression assessment and management
- Social work and case management
- Supportive care

Referenced with permission from the NCCN Clinical Practice Guidelines in Oncology (NCCN Guidelines®) for Head and Neck Cancers V.2.2016. © National Comprehensive Cancer Network, Inc 2016. All rights reserved. Accessed November 2, 2016. To view the most recent and complete version of the guideline, go online to NCCN.org. NATIONAL COMPREHENSIVE CANCER NETWORK®, NCCN®, NCCN GUIDELINES®, and all other NCCN Content are trademarks owned by the National Comprehensive Cancer Network, Inc.

AXIS
Medical Education

► The multidisciplinary team is more than three physicians. One can see that there are reconstructive physicians, dentists, and prosthodontists. There are accessory allied health clinicians who are knowledgeable in nutrition, symptom management, hearing, speech and swallowing, and cessation of smoking and alcohol, which may have led to development of the cancer in the first place. Pathologists, radiologists, and other diagnostic scientists are important for ensuring that the disease is appropriately characterized; and in particular, the molecular anatomic characterization, as we've discussed, is important for risk stratification and entry onto clinical trials.

American Cancer Society Guidelines for Head and Neck Cancer Survivorship Care: March 2016

Focus on 5 key areas of survivorship for a population that faces potentially significant physical, psychosocial, and practical effects from the cancer and its treatment:

1. Surveillance for head and neck cancer recurrence
2. Screening and early detection of second primary cancers
3. Assessment and management of physical and psychosocial long-term and late effects of head and neck cancer and its treatment
4. Health promotion
5. Care coordination and practice implications

Cohen et al. *CA Cancer J Clin.* 2016;66:203-239.

AXIS
Medical Education

- The American Cancer Society has guidelines for survivorship; these were presented and published in March of 2016. They focus on areas of survivorship that a population faces with impact on physical, psychosocial, and practical effects from cancer and its treatment. These are shown here. These are particularly highlighting surveillance, screening, assessment, health promotion, and care coordination with implications for practice.

AXIS

Current Therapeutic Options in Head and Neck Cancers

- Now we'll discuss current therapeutic options in head and neck cancers.

Current Trends and Concepts

- Non-surgical therapy of tumors of the tonsil and tongue base have been favored for 10-15 years
- Factors associated with this trend
 - Similar overall treatment results
 - Morbidity and functional impairment associated with surgery
 - Chemotherapy/radiation therapy sensitivity implied by trial results
 - Minimally invasive surgical options evolving and practiced only at few centers

AXIS
Medical Education

► It's important to recognize that because of the some of the morbidity of surgical therapy, in particular, there's been a shift away over the past 20 years from surgical therapy, and chemoradiation or nonsurgical therapy became favored over the past 10 or 15 years. This has changed over the past 5 or 6 years, as we will discuss, but up until the availability of minimally invasive surgery the chemoradiation nonsurgical treatment was providing similar overall treatment results, there was less acute morbidity and functional impairment, as we saw with major surgical procedures. Chemotherapy and radiation therapy appeared to be quite effective, and head and neck cancer appeared to be a chemoradiation-sensitive disease. Until the past 5 years, there were very few centers practicing minimally invasive surgery. This has changed, and we'll get into some of the progress in minimally invasive surgery and its role in the multidisciplinary care of head and neck cancer.

Long-Term Toxicity of Chemo-Radiation Therapy

- Long-term morbidity from chemo-radiation therapy in 3 prospective clinical trials
- 99/230 (43%) with “severe” late toxicity

VOLUME 20 • NUMBER 21 • JULY 20 2009

JOURNAL OF CLINICAL ONCOLOGY ORIGINAL REPORT

Factors Associated With Severe Late Toxicity After Concurrent Chemoradiation for Locally Advanced Head and Neck Cancer: An RTOG Analysis

Mitchell Machtay, Jennifer Moughan, Andrew Trotti, Adam S. Garden, Randal S. Weber, Jay S. Cooper, Arlene Forastiere, and K. Kian Ang

Table 3. Types of Late Toxicity Events Seen by Trial

Variable	91-11	97-03	99-14	Total
Feeding tube dependence > 2 years post-radiation therapy	—*	29*		29
RTOG late toxicity criteria, grade 3+				
Pharyngeal dysfunction	16	28	19	63
Laryngeal dysfunction	22	6	0	28
Death	11	9	2	22
Other (eg, infection, fistula)	3	0	1	4
Any	38†	40†	21†	99†
No severe late toxicity event (controls)	50	62	19	13

Abbreviation: RTOG, Radiation Therapy Oncology Group.
 *Feeding tube data were not collected at all in RTOG study 91-11.
 †Numbers do not always add up along columns, due to some patients having more than one toxicity event.

Machtay et al. *J Clin Oncol*. 2008;26:3582-3589.

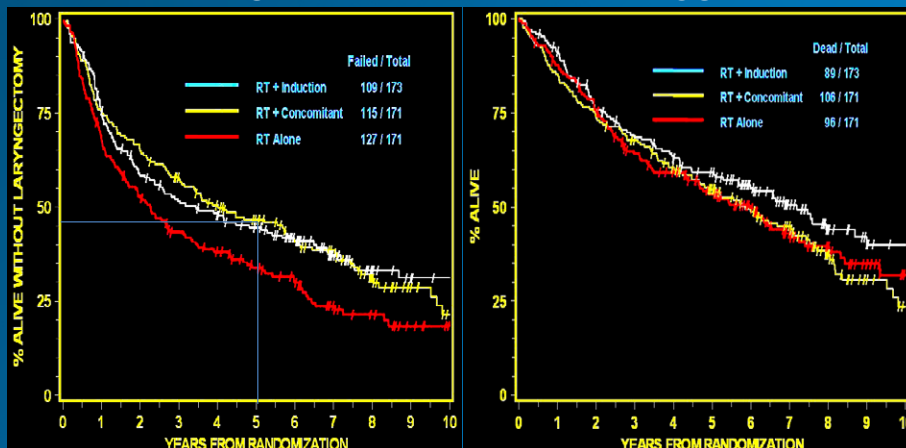
AXIS
Medical Education

► As I mentioned, the shift toward chemoradiation over the past 15 to 20 years led to the recognition that there was actually not only acute side effects, but also long-term morbidity of chemoradiation therapy. This is an assessment of 3 different Radiation Therapy Oncology Group trials employing chemoradiation with high-dose cisplatin plus radiation therapy. As you can see in these 3 Radiation Therapy Oncology Group trials, there was a 45% “severe” late toxicity experienced by patients who were otherwise cured of disease. So in this setting, the potential for reduced intensity therapy with such good oncologic outcomes, as we see in HPV-positive disease, became popularized.

RTOG 91-11: 10-Year Update CRT and Late Non-Cancer Deaths

LFS

OS



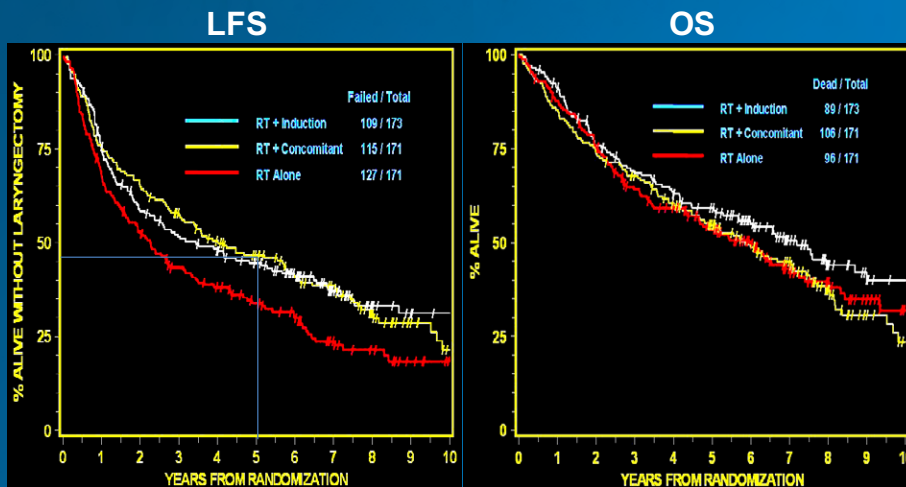
CRT, chemo-radiation therapy; LFS, laryngectomy-free survival; OS, overall survival; RT, radiation therapy.
 Forastiere et al. *J Clin Oncol*. 2013;31:845-852.

AXIS
Medical Education

► It's also important to know that the organ preservation that was implemented in the Radiation Therapy Oncology Group trial 91-11 was updated. The long-term results appeared to have a different conclusion than the initial 2-year data. The 2-year data suggested that concomitant chemoradiation was the optimal treatment choice for larynx preservation in patients with advanced cancer of the larynx or voice box. However, what you can see here is that long-term data suggested that induction chemotherapy followed by radiation therapy had similar overall oncologic efficacy. On the right-hand side of the slide, in the white curve, the induction chemotherapy followed by radiation actually appeared to have better overall survival.

(cont'd on next page)

RTOG 91-11: 10-Year Update CRT and Late Non-Cancer Deaths



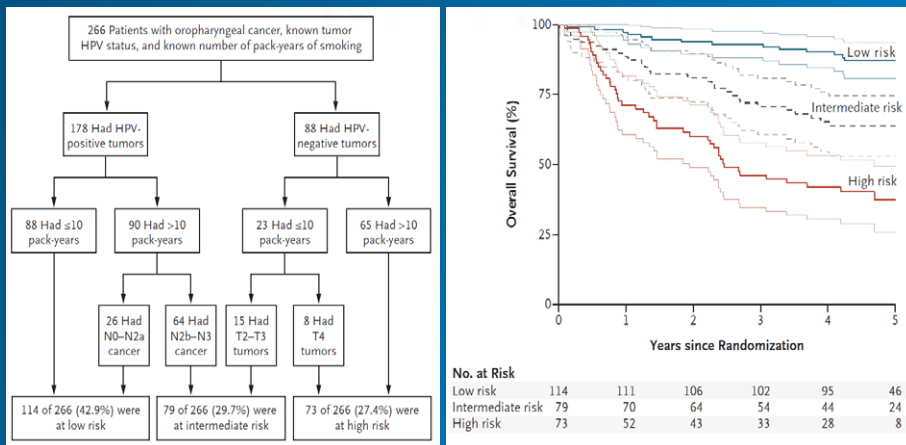
CRT, chemo-radiation therapy; LFS, laryngectomy-free survival; OS, overall survival; RT, radiation therapy.
Forastiere et al. *J Clin Oncol*. 2013;31:845-852.

AXIS
Medical Education

(cont'd from previous page)

This was possibly due to non-cancer deaths. The exact reason for some of those deaths—in the yellow curve, the concomitant chemoradiation arm—is not clear, but may be due to some of the toxicities of the intensified therapy.

Risk Stratification Drives Therapeutic Choices



3-year OS 93.0% (95% CI, 88.3 to 97.7) in the low-risk group,
70.8% (95% CI, 60.7 to 80.8) in the intermediate-risk group

Ang and Gillison. *N Engl J Med*. 2010;363:24-35.

AXIS
Medical Education

► So, we talked a bit about risk stratification. It's important to know that we now are able to use this in the clinic. As I mentioned, the low-risk patients are potential candidates for reduced chemotherapy or radiation. The high-risk patients need to be intensified in their therapy. Recognizing that the side effects may be long term and permanent, we need to balance this in our therapeutic decision making.

NCCN Guidelines®: Systemic Therapy for Recurrent, Unresectable, or Metastatic Disease* (with no surgery or RT Option)

- Choice should be individualized based on patient characteristics (PS, goals of therapy)
- Unless otherwise specified, regimens listed below can be used for either nasopharyngeal or non-nasopharyngeal cancer
- Updated October 2016 to include single agent pembrolizumab and nivolumab (category 1) if disease progression on or after platinum-containing chemotherapy for the treatment of recurrent or metastatic disease

Combination Therapy

- Cisplatin or carboplatin + 5-FU + cetuximab (non-nasopharyngeal; category 1)
- Cisplatin or carboplatin + docetaxel or paclitaxel
- Cisplatin/cetuximab (non-nasopharyngeal)
- Cisplatin/5-FU
- Cisplatin/docetaxel/cetuximab (non-nasopharyngeal)
- Cisplatin/paclitaxel/cetuximab (non-nasopharyngeal)
- Carboplatin/cetuximab (nasopharyngeal)
- Cisplatin/gemcitabine (nasopharyngeal)
- Gemcitabine/vinorelbine (nasopharyngeal)

Single Agents

- Cisplatin
- Carboplatin
- Paclitaxel
- Docetaxel
- 5-FU
- Methotrexate
- Cetuximab (non-nasopharyngeal)
- Gemcitabine (nasopharyngeal)
- Capecitabine
- Vinorelbine (non-nasopharyngeal)
- Afatinib (non-nasopharyngeal; second line; category 2B)
- Pembrolizumab (if disease progression on or after platinum-containing chemotherapy)
- Nivolumab (if disease progression on or after platinum-containing chemotherapy; category 1)

5-FU, 5-fluorouracil; PS, performance status; RT, radiation therapy.

*As of October 12, 2016.

Note: All recommendations are category 2A unless otherwise indicated.

Clinical trials: NCCN believes that the best management of any patient with cancer is in a clinical trial. Participation in clinical trials is especially encouraged.

Referenced with permission from the NCCN Clinical Practice Guidelines in Oncology (NCCN Guidelines®) for Head and Neck Cancers V.2.2016. © National Comprehensive Cancer Network, Inc. 2016. All rights reserved. Accessed November 2, 2016. To view the most recent and complete version of the guideline, go online to NCCN.org. NATIONAL COMPREHENSIVE CANCER NETWORK®, NCCN®, NCCN GUIDELINES®, and all other NCCN Content are trademarks owned by the National Comprehensive Cancer Network, Inc.



► The National Comprehensive Cancer Network guidelines demonstrate the different therapy—both combination and single agents—and these have been used to try to improve survival for the high-risk patients. That's recurrent metastatic disease. We should also recognize that chemotherapy is not the only systemic therapy for head and neck cancer. In 2006, the FDA approved the first head and neck cancer treatment in 45 years, which was cetuximab. This is an epidermal growth factor receptor targeted antibody.

Cetuximab

- EGFR overexpressed in >90% of SCCHN
- Overexpression of EGFR is a strong and independent unfavorable prognostic factor in SCCHN, which has led to the development of EGFR inhibitors, such as cetuximab
- FDA approved cetuximab in combination with RT for the initial treatment of locally or regionally advanced SCCHN, and as a single agent for the treatment of patients with recurrent or metastatic SCCHN in which prior platinum-based therapy has failed
- Randomized, multicenter, controlled trial of 424 patients with locally or regionally advanced SCCHN
 - Median duration of locoregional control: 24.4 months among patients treated with cetuximab plus RT and 14.9 months among patients treated with RT alone (HR 0.68, $P = .005$)
 - Cetuximab plus RT also improved median OS and PFS over RT alone
 - Common adverse reactions with cetuximab treatment included acneiform rash and infusion reactions

EGFR, epidermal growth factor receptor; FDA, US Food and Drug Administration; OS, overall survival; PFS, progression-free survival; RT, radiation therapy; SCCHN, squamous cell carcinoma of the head and neck. Bonner et al. *N Engl J Med*. 2006;354:567-578; FDA News Release, 2006; Pfister et al, 2016.



► Cetuximab targets EGFR, which is overexpressed in over 90% of head and neck cancers. We know that the overexpression of EGFR is an independent, unfavorable prognostic factor. So, the development of EGFR-specific inhibitors led to a new era combining cetuximab with radiotherapy in locally advanced head and neck cancer. In the trial published in 2006, the duration of locoregional control was improved. There is an absolute overall survival benefit of 8% to 10% with the addition of cetuximab over radiation alone. The adverse reactions were tolerable. These included acneiform rash and infusion reactions and some overlap of mucositis in the radiation field.

Cetuximab: EXTREME Trial

- Cetuximab plus platinum-based chemotherapy as first-line treatment in 442 patients with untreated recurrent or metastatic SCCHN
 - 220 patients cisplatin or carboplatin plus fluorouracil every 3 weeks for a maximum of 6 cycles
 - 222 patients cisplatin or carboplatin plus fluorouracil plus cetuximab for a maximum of 6 cycles
- Median OS: cetuximab plus platinum-based therapy and 5-FU significantly prolonged median OS compared to platinum-based therapy and 5-FU alone
 - 10.1 months vs 7.4 months
 - HR 0.80
 - $P = .04$
- The most common grade 3 or 4 adverse events in the cetuximab group were anemia (13%), neutropenia (22%), and thrombocytopenia (11%)
- 2011: FDA approved cetuximab in combination with platinum-based therapy with 5-FU for the first-line treatment of patients with recurrent locoregional disease or metastatic SCCHN

5-FU, 5-fluorouracil; FDA, US Food and Drug Administration; OS, overall survival; SCCHN, squamous cell carcinoma of the head and neck. Vermorken et al. *N Engl J Med*. 2008;359:1116-1127; FDA News Release, 2011.

AXIS
Medical Education

▶ Cetuximab is not only effective in locally advanced head and neck cancer, but also in recurrent metastatic disease. In the so-called EXTREME trial, which combined cetuximab with platinum 5-fluorouracil (5-FU), demonstrated a statistically significant survival benefit in first-line recurrent metastatic head and neck cancer. This was the combination of a platinum-based therapy with 5-FU in a randomized phase 3 design; adding cetuximab demonstrating that there was ability to tolerate the addition of cetuximab, and there was an increase of 2.5 months with a hazard ratio of 0.8. The grade 3 and 4 adverse events were, as expected, anemia, neutropenia, and thrombocytopenia. In 2011, the EXTREME regimen of cetuximab plus platinum 5-FU was FDA approved for first-line recurrent metastatic or recurrent head and neck cancer.

Cetuximab: Recent Data

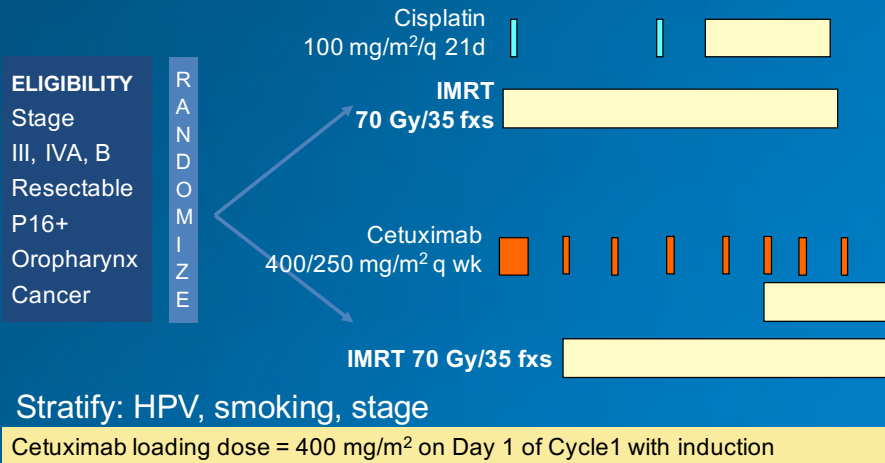
- Efficacy in HPV-negative locoregionally advanced SCCHN and poor prognosis
 - Adding cetuximab to induction chemotherapy and hyperfractionated or accelerated chemo-RT therapy improved long-term disease control in patients with HPV-negative locoregionally advanced SCCHN and poor prognosis in a phase 2 trial (Melotek et al, 2016)
 - OS at 5 years: 80.3% for the entire cohort vs. 72.5% for the HPV-negative cohort
 - PFS at 5 year: 74.1% for the entire cohort vs. 65.9% for the HPV-negative cohort
 - No significant differences between chemo-RT platforms
- Combination of pazopanib and cetuximab demonstrated promising efficacy in phase 1 trial, with a disease control rate of 77% in patients with recurrent or metastatic SCCHN, including patients with cetuximab- or platinum-resistant disease (Adkins et al, 2016)
- Retrospective analysis of phase 3 registration trial IMCL-9815 to examine association of HPV and p16 protein expression status with outcomes in patients with oropharyngeal carcinoma receiving RT plus cetuximab or RT alone showed benefit for the addition of cetuximab to RT regardless of p16 or HPV status versus RT alone (Rosenthal et al, 2015)

▶ Recent data have tried to add cetuximab to chemoradiation in the RTOG 05-22. This did not demonstrate positivity. So, the addition of cetuximab did not improve survival in cisplatin radiation-treated patients. Other combinations of cetuximab have been used, but so far, none of these have improved survival over cetuximab, radiation alone, or cisplatin and radiation. These are the two current standards of care.

HPV, human papillomavirus; OS, overall survival; PFS, progression-free survival; RT, radiation therapy; SCCHN, squamous cell carcinoma of the head and neck. Adkins et al, 2016; Melotek et al. *Radiat Oncol*. 2016;94:867; Rosenthal et al. *J Clin Oncol*. 2016;34:1300-1308.

AXIS
Medical Education

RTOG 1016: A Randomized Phase 3 Trial of Chemo-Radiation Therapy With Cisplatin or Cetuximab in P16+ Oropharynx Cancer

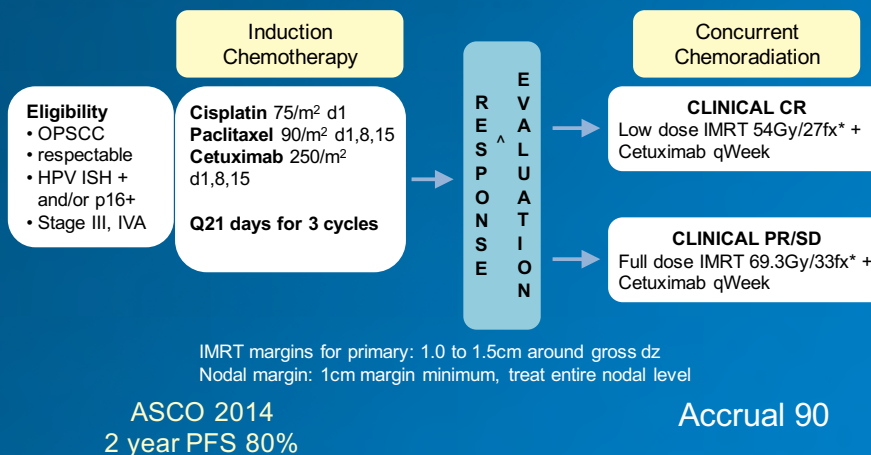


HPV, human papillomavirus; IMRT, intensity-modulated radiation therapy.
ClinicalTrials.gov; NCT01302834.

AXIS
Medical Education

► Because these are the two standards of care for locally advanced disease, a head-to-head phase 3 trial—the RTOG 1016—was completed. This was a randomized phase 3 trial comparing chemoradiation therapy with cisplatin or cetuximab specifically in the patients with HPV-positive oropharynx cancer using p16 positivity as a surrogate biomarker for HPV status. This trial enrolled almost 1,000 patients. The attempt was to get rid of cytotoxic chemotherapy and replace it with cetuximab, maintaining the 70 Gy radiation with standard fractionation. That study is completed and awaiting maturation.

ECOG 1308 Induction Followed by Reduced-Dose (54 Gy) IMRT/Cetuximab



CR, complete response; HPV, human papillomavirus; IMRT, intensity-modulated radiation therapy; PFS, progression-free survival; PR, partial response; SD, stable disease.
Cmelak et al, *J Clin Oncol*. 2014;32: abstract LBA6006; NCT01084083.

AXIS
Medical Education

► The first clinical trial actually in HPV-positive patients was an attempt to de-intensify radiation therapy. This is the ECOG 1308 trial, which used a 3-drug induction chemotherapy with a response evaluation after the 9 weeks of induction chemotherapy using cisplatin, paclitaxel, and cetuximab. In patients who had a complete clinical response, they were eligible for lower-dose radiation of 54 Gy combined with cetuximab. If there was less than a complete response, then patients got the standard of care, 69 to 70 Gy, with cetuximab. It turns out that about 70% of patients had complete clinical responses and went on to receive reduced dose radiotherapy of 54 Gy.

NRG-HN002: A Randomized Phase 2 Trial for HPV-Positive, Non-Smoking–Associated, Locoregionally Advanced Oropharyngeal Cancer Patients

Eligibility

- Oropharyngeal SCC
- HPV+
- ≤10 pack-year
- T1-T2 N1-N2b
- T3 N0-N2b

44% of RTOG 1016 population eligible:
~15 patients/month

R
A
N
D
O
M
I
Z
E

60 Gy radiation (2.0 Gy/fraction) in 6 weeks + concurrent cisplatin 40 mg/m² weekly × 6 cycles

60 Gy radiation (2.0 Gy/fraction, 6 fractions/week) in 5 weeks

HPV, human papillomavirus; SCC, squamous cell carcinoma.
Sue Yom; NCT02254278.

AXIS
Medical Education

► Having demonstrated the feasibility, the RTOG—now under the umbrella of the NRG Cooperative Group—designed the HN002 clinical trial. This was a randomized phase 2 trial for HPV-positive low-risk patients who are never smokers (meaning less than 10 pack year) and have low to intermediate tumor bulk. So these are patients with T1-T2 N1-N2b. These patients have both de-intensification of radiation—at 60 Gy instead of 70 Gy—and half of them in this randomized design have no chemotherapy given. So this is a randomized trial of 60 Gy of radiation plus weekly cisplatin versus 60 Gy of radiation alone. The trial is accruing briskly; it has an accrual goal of 300 patients, and I think is about two-thirds of the way there as of late November 2016.

What Then Is The Role of Surgery?

- Best opportunity to biologically stage disease so that adjunctive therapy can be used in a judicious manner
 - ?pN stage / ?ECS status
- Advent of trans-oral approaches and improved surgical tools allow better access, exposure, and consequently control on surgical margins
 - Transoral laser oropharyngectomy
 - Transoral Robotic Surgery (TORS)
- Advent of selective neck dissection allows neck treatment without adding significant morbidity to surgical therapy

AXIS
Medical Education

► So what is the role of surgery in locally advanced head and neck cancer? As I mentioned, usually the surgeon's role is to provide the most accurate disease stage because this often drives the treatment choices. We've had improvements in transoral minimally invasive surgical approaches with better access, exposure, and better control on surgical margins to achieve an R0 resection in a lower morbidity approach with either transoral laser or transoral robotic surgery. In addition, staging of the neck with a selective neck dissection can be accomplished without adding significant morbidity to surgical therapy, which is transoral. This has led to the potential reintroduction of surgical therapy.

Phase 2 Randomized Trial of Transoral Surgical Resection followed by Low-Dose or Standard-Dose IMRT in Resectable p16+ Locally Advanced Oropharynx Cancer (E3311)

- p16+, Stage III/IV (cT1-2N1-N2b) OPSCC
- Stratify by stage and smoking status
- Initial and Ongoing credentialing of surgeon required as part of site participation in the trial
- Pathology analysis for margins/ECS
- MBS credentialing and synchronization

ECS, extracapsular spread; IMRT, intensity-modulated radiation therapy; MBS, modified barium swallow; OPSCC, oropharyngeal squamous cell carcinoma. NCT01898494.



► This led to the design of a phase 2 randomized trial of transoral surgical therapy. This is the ECOG 3311 trial. This is a study of upfront transoral surgical therapy followed by a randomization to low dose or standard dose intensity-modulated radiotherapy for a resectable HPV or p16+ locally advanced oropharynx cancers. This trial enrolls stage III and IV disease. Clinical stage T1 to T2, N1 to N2b. It stratifies both by stage and smoking status. This trial is novel and innovative because it integrates credentialing of the surgeon. There are 75 credentialed surgeons at over 50 sites across the US. There is standardization of pathology analysis for margin evaluation and extracapsular spread in the lymph nodes. There are harmonized and synchronized modified barium swallows to determine the impact on quality of life and patient swallowing throughout the surgical therapy and postoperative therapy.

E3311 Trial Design

- Patients with pT1-T2N0-N1 will be observed (Arm A)
- Patients with clear/close margins, ≤ 1 mm ECS, PNI/LVI, and/or 2-4 metastatic LNs will be randomized to 50 Gy vs. 60 Gy (Arms B & C)
- Patients with positive margins, ≥ 5 metastatic LN, and/or >1 mm ECS will be treated with standard-dose (66Gy) RT + cisplatin (Arm D)
- **Primary objective** to evaluate the 2-yr PFS in HPV+ OPSCC patients treated with low-dose RT (assume 85% per arm)
- **Secondary endpoints:** Early/late toxicities, swallowing function, QOL, and oral/serum/tissue biomarkers in predicting clinical outcome. [Stopping rules for bleeding, recurrence]

ECS, extracapsular spread; HPV, human papillomavirus; LNs, lymph nodes; LVI, lymphovascular invasion; OPSCC, oropharyngeal squamous cell carcinoma; PFS, progression-free survival; PNI, perineural invasion; QOL, quality of life; RT, radiation therapy. NCT01898494.



► There are four different arms. Arm A is for observation for patients with documented low-risk disease stage 1 to 2 and early stage 3. These patients can be observed. The patients with clear or close margins that have microscopic extracapsular spread, perineural invasion, or up to 4 metastatic lymph nodes are in the randomization and receive either 50 Gy or 60 Gy on Arms B or C, respectively. In patients with positive margins, 5 or more metastatic lymph nodes, or gross macroscopic extracapsular spread are treated with standard postoperative chemoradiation with weekly cisplatin and 66 Gy.

(cont'd on next page)

E3311 Trial Design

- Patients with pT1-T2N0-N1 will be observed (Arm A)
- Patients with clear/close margins, ≤ 1 mm ECS, PNI/LVI, and/or 2-4 metastatic LNs will be randomized to 50 Gy vs. 60 Gy (Arms B & C)
- Patients with positive margins, ≥ 5 metastatic LN, and/or > 1 mm ECS will be treated with standard-dose (66Gy) RT + cisplatin (Arm D)
- **Primary objective** to evaluate the 2-yr PFS in HPV+ OPSCC patients treated with low-dose RT (assume 85% per arm)
- **Secondary endpoints:** Early/late toxicities, swallowing function, QOL, and oral/serum/tissue biomarkers in predicting clinical outcome. [Stopping rules for bleeding, recurrence]

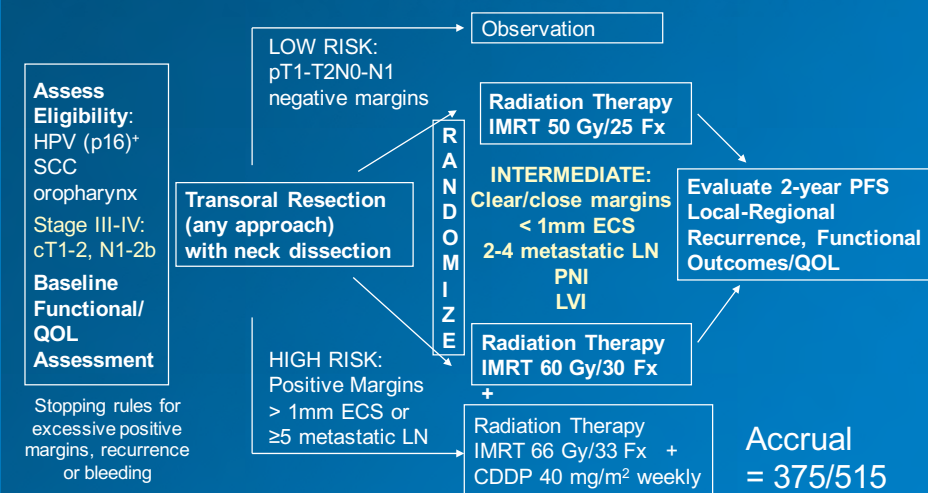
ECS, extracapsular spread; HPV, human papillomavirus; LNs, lymph nodes; LVI, lymphovascular invasion; OPSCC, oropharyngeal squamous cell carcinoma; PFS, progression-free survival; PNI, perineural invasion; QOL, quality of life; RT, radiation therapy.
NCT01898494.

AXIS
Medical Education

(cont'd from previous page)

The primary objective is to evaluate the 2-year progression-free survival in HPV-positive resected patients with oropharynx cancer, assuming 85% two-year progression-free survival with either 50 Gy or 60 Gy. A series of secondary endpoints are being evaluated including toxicities, swallowing function, and quality of life.

ECOG 3311 HPV+/*p16*+ Trial Schema



ECS, extracapsular spread; HPV, human papillomavirus; LNs, lymph nodes; LVI, lymphovascular invasion; OPSCC, oropharyngeal squamous cell carcinoma; PFS, progression-free survival; PNI, perineural invasion; QOL, quality of life; RT, radiation therapy; SCC, squamous cell carcinoma.
NCT01898494.

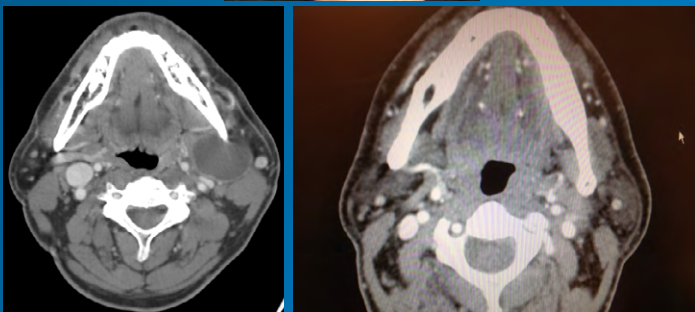
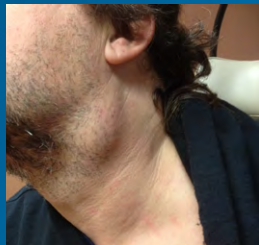AXIS
Medical Education

► Here's the schema. One can see that the randomization of the intermediate-risk patients with clear or close margins, microscopic ECS, and up to 4 metastatic lymph nodes. And this trial is accruing well also.

- Now we'll talk about the practical application case of initial treatment.

Practical Application Case: Initial Treatment

A Neck Mass in an Adult



- Here's a patient who comes in without traditional risk factors. We know that a neck mass that occurs in adult must be ruled out for cancer. One can see a cystic neck mass in level 2.

Images courtesy of Robert L. Ferris, MD, PhD.

Case 1

- The patient is a 45-year-old man
- Healthy, no smoking, glass of wine on weekends
- No significant comorbidities
- He presents to his physician with a painless left neck mass, but otherwise exhibits no additional symptoms
- After 2 courses of antibiotics without any improvement, his physician refers him to a head and neck cancer specialist

AXIS
Medical Education

► This is a 45-year-old patient who's healthy, no real comorbidities, no smoking exposure, only occasional social alcohol exposure, and has a painless left neck mass that does respond to antibiotics. He's been referred to a head and neck cancer specialist.

Case 1 (cont)

- A physical examination clearly shows a slightly indurated enlarged left BOT
- A fiberoptic office exam shows no clear vallecula involvement
- A neck exam reveals 1 enlarged lymph node in level 2, 4 cm in size
- HPV by *p16* and ISH is positive
- CT and PET confirm T1N2aM0

AXIS
Medical Education

► On physical examination, this shows induration and enlargement of the left base of tongue. The fiberoptic exam shows no clear involvement of the vallecula. There is the single large enlarged lymph node in level 2, which is 4 cm in size. A needle biopsy demonstrates that there is a p16 and immunohistochemical exam evaluation of p16 is strongly and diffusely positive. This is a surrogate for HPV status, which is confirmed when in situ hybridization for HPV DNA is performed. The CT and PET scan confirm a T1N2aM0 patient, stage 4, HPV-positive head and neck cancer.

BOT, base of tongue; CT, computed tomography; PET, positron emission tomography.

Case 1 Question 1: How Would You Treat this Patient?

- a) Concurrent chemo-radiation therapy with either cisplatin or carboplatin/paclitaxel
- b) Cetuximab weekly and radiation
- c) Low-dose radiation given HPV status
- d) Surgery followed by definitive radiation or chemo-radiation therapy
- e) Induction chemotherapy followed by concurrent chemo-radiation therapy



► In this setting, the patient has multiple different options, and these are often driven by where the patient presents, which location in the US and which institution or cancer specialist. Because there are nonsurgical options either with concurrent chemoradiation or cetuximab radiation. Some centers because of the better clinical outcome might attempt to reduce the dose of radiation therapy, as we've seen on some of the prospective clinical trials. Upfront surgery in the appropriate center with an experienced clinician and transoral robotic or laser surgery is possible with risk-adjusted postoperative adjuvant therapy. In some centers, induction chemotherapy is still used followed by concurrent chemoradiation.

RT Versus Surgery: Similar Survival

- Mendenhall et al (2000) – RT for Tonsil cancer
 - 5-year local control rates: T1 83%, T2 81%, T3 74%, and T4 60%
 - 5-year cause-specific survival rates, by disease stage: I-100%, II-86%, III-82%, and IVa-63%
- Selek et al (2004) – RT for Early Stage OP cancer
 - 5-year local, regional, locoregional, and disease-specific survival rates: 85%, 93%, 81%, and 77%, respectively

► We know that radiation therapy versus surgery have similar survival in outcomes. We don't yet have good data on functional outcomes, but one can see that these are similar modalities, and patient preference plays a role in treatment choices.



Radiation Therapy – Limitations

- Full course radiation therapy can be offered only once; the rate of second primary cancers of the head neck among patients with oral and OPSCC is 20% to 27%
- Radiation therapy and CRT are also associated with significant short- and long-term adverse effects
- This is more relevant today --> a younger HPV-positive OPSCC survivor will tend to live longer, being more susceptible to either late adverse effects or need radiation therapy in the future for a second primary

CRT, chemo-radiation therapy; HPV, human papillomavirus; OPSCC, oropharyngeal squamous cell carcinoma.



- ▶ Limitations with radiation include that full-course radiation therapy can usually only be offered once to the head and neck. And because of the rate of second primary tumors, which may be 20% to 25% over the life of the patient, that we often try to reserve radiation therapy if possible and other options are available. We've discussed the short- and long-term adverse events. Because of these long-term adverse events, the younger HPV-positive oropharynx cancer survivors have a much more delicate or vulnerability to the exposure to long-term adverse events and the risk of a second primary.

What Then Is the Role of Surgery?

- Best opportunity to biologically stage disease so that adjuvant therapy can be used in a judicious manner and dose
 - ?pN stage/?ECS status
- Advent of trans-oral approaches and improved surgical tools allow better access, exposure, and consequently control of surgical margins
 - Transoral laser oropharyngectomy for SCC tonsil
 - Transoral robotic surgery for base of tongue neoplasms
- Advent of selective neck dissection allows neck treatment without adding significant morbidity to surgical therapy

ECS, extracapsular spread; SCC, squamous cell carcinoma.



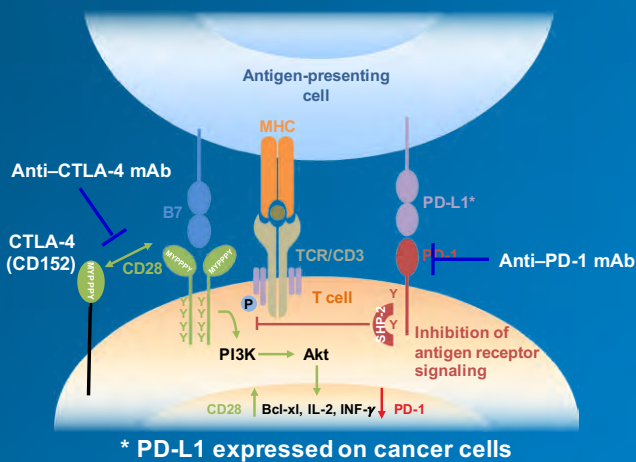
- ▶ We've talked about the role of surgery. And so, I think it's important to focus on new therapies because we have really evaluated and tested combinations of the three modalities: surgery, radiation, and chemotherapy.

Ongoing Clinical Research: A Focus on Checkpoint Inhibitors

- We now have this fourth modality of immunotherapy, which is characterized by immune checkpoint inhibitors, we'll discuss now.

Blocking Inhibitory Receptors to Reactivate Exhausted T cells

New immunotherapeutic targets: CTLA-4 and PD-1



CTLA-4, cytotoxic T-lymphocyte-associated antigen 4; mAb, monoclonal antibody; PD-1, programmed cell death protein 1; PD-L, programmed cell death protein ligand 1.
Modified from *Annu Rev Immunol.* 2008;26:677-704.

- I mentioned that the signal 2 of the immune system in normal activation can either be a beneficial positive signal or an inhibitory signal. The checkpoint receptors represent the inhibitory signal 2. And these are driven through CTLA-4, PD-1, or a long list of other immune checkpoint receptors. These are potential therapeutic targets with the goal of blocking the inhibitory checkpoint or co-inhibitory molecules and reactivating the positive CD28 costimulatory signal in the antitumor T cell. We can use anti-CTLA-4 or anti-PD-1. This permits the T-cell receptor signal 1 and the CD28 positive signal 2 to reactivate these antitumor T cells.

Therapies to “Drive” an Immune Response



- Vaccines
- Adoptive T-cell therapies
 - CAR-T
 - TIL therapy



- Cytokines
- TLR agonists
- Agonist antibodies (4-1BB, OX-40)



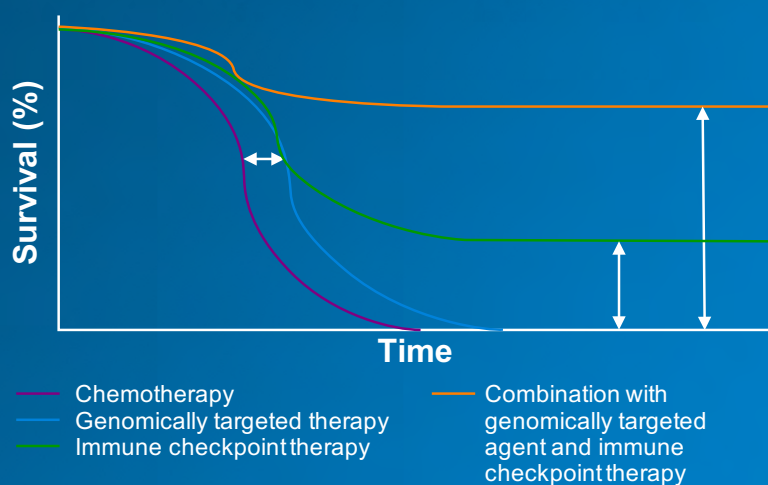
- Checkpoint blockade (mAbs blocking CTLA-4, PD-1, PD-L1)

CAR-T, chimeric antigen receptor T cell; CTLA-4, cytotoxic T-lymphocyte-associated antigen 4; mAbs, monoclonal antibodies; PD-1, programmed cell death protein 1; PD-L, programmed cell death protein ligand 1; TIL, tumor infiltrating lymphocytes.

AXIS
Medical Education

► It's important to recognize that the immune system is driven by a series of steps, which we've discussed. We can “start the ignition” with vaccines, with adoptive cell therapies. We can “push on the gas” with cytokines that are generating inflammation, Toll-like receptor agonists some of which are in the clinic, and agonistic antibodies that drive a positive signal 2 such as through the OX-40 or 4-1BB costimulatory signal 2s. Then, as we've discussed, the checkpoint blockade through monoclonal antibodies blocking CTLA-4 or the PD-1/PD-L1 access allow us to “take off the brakes” and increase the antitumor immune activity.

The Promise of Immunotherapy: The Kaplan-Meier Curve Tail



Adapted from Sharma & Allison. *Cell* 2015;161:205-214.

AXIS
Medical Education

► So immunotherapy has provided promise up until its clinical activity in the past year. And what we've seen is that the traditional genomically targeted therapies such as cetuximab and small molecules have only pushed the survival curve over, and eventually resistance develops. The immune checkpoint therapy brings promise for the durability of the immune response and long-term memory leading to the tail, as shown in the green bar, where long-term durability and immune memory may provide clinical control of the tumor and tumor stability and complete and partial responses. Now we've moved successful immunotherapy and have observed this tail into locally advanced disease, and I'll discuss some of those clinical trials now combining immunotherapy and immune checkpoint therapy into locally advanced chemoradiation therapy.

Pembrolizumab: Phase 1 KEYNOTE-012 Trial

- Anti-PD-1 agent
- Phase 1b KEYNOTE-012 trial of pembrolizumab monotherapy
- Patients with recurrent or metastatic HNSCC who had disease progression on or after platinum-containing chemotherapy or following platinum-containing chemotherapy administered as part of induction, concurrent, or adjuvant therapy and ECOG PS 0 or 1
- 78% PD-L1 positive
- 60 patients enrolled and treated
- Overall response by central imaging review:
 - 18% (8/45 patients; 95% CI 8-32) in all patients
 - 25% (4/16 patients; 95% CI 7-52) in HPV-positive patients
 - 14% (4/29 patients; 95% CI 4-32) in HPV-negative patients
- Immune-mediated adverse reactions occurred with pembrolizumab including pneumonitis, colitis, hepatitis, endocrinopathies, and nephritis

DoR, duration of response; ECOG PS, Eastern Cooperative Oncology Group performance status; HNSCC, head and neck squamous cell carcinoma; HPV, human papillomavirus; PD-1, programmed cell death protein 1; PD-L1, programmed cell death protein ligand 1. Seiwert et al, *J Clin Oncol*. 2015;33: abstract LBA6008; *Lancet Oncol*. 2016;17:956-965; Chow et al, *J Clin Oncol*. 2016; FDA News Release, 2016.

AXIS
Medical Education

► The first antibody, pembrolizumab, targeting PD-1 was presented at the ASCO meeting in 2014 from a phase 1b clinical trial called KEYNOTE-012. This is an anti-PD-1 antibody. Monotherapy using pembrolizumab was used in patients with recurrent metastatic head and neck cancer that progressed after a platinum-containing chemotherapy. These patients were also tested for expression of the ligand, PD-L1. Interestingly, an overall response by central imaging review demonstrated an 18% overall response rate. This appeared to be a bit higher in the HPV-positive patients (25%) and a bit lower (14%) in the HPV-negative patients, although the numbers are somewhat small. This was also the first immune therapy in head and neck cancer, and this led us to understand that there are some unique select adverse events that are characteristic of immune-mediated reactions such as pneumonitis, colitis, hepatitis, and endocrinopathies.

Pembrolizumab FDA Approval

- **August 2016:** FDA granted accelerated approval to pembrolizumab for the treatment of patients with recurrent or metastatic head and neck squamous cell carcinoma with disease progression on or after platinum-containing chemotherapy

FDA, US Food and Drug Administration.
FDA News Release, 2016.

AXIS
Medical Education

- ▶ Pembrolizumab was FDA approved, in part, based on the KEYNOTE-012 data in August of 2016, and the labeling description is shown here.

Other Pembrolizumab Trials

- Phase 3 KEYNOTE-040 trial (confirmatory trial to KEYNOTE-012):
 - Pembrolizumab or standard treatment with methotrexate, docetaxel, or cetuximab in patients with SCCHN
 - Study ongoing, not recruiting participants*
- Phase 3 KEYNOTE-048 trial:
 - Pembrolizumab single agent, or combined with standard treatment (platinum + 5-FU), or standard treatment alone (cetuximab + platinum + 5-FU) in the first-line treatment of recurrent/metastatic SCCHN
 - Currently recruiting participants*
- Phase 2 KEYNOTE-055 trial:
 - Pembrolizumab after progression on platinum and cetuximab in R/M HNSCC
 - Preliminary results presented at ASCO 2016
 - ORR 17-18%; OS 8 months; manageable safety profile

*As of October 2016.
5-FU, 5-fluorouracil; M, metastatic; ORR, objective response rate; OS, overall survival; R, recurrent; SCCHN, squamous cell cancer of the head and neck.
Merck Sharp & Dohme Corp, NCT02252042; NCT02358031; NCT02255097; Baumi et al, *J Clin Oncol*. 2016;34: abstract 6011.

AXIS
Medical Education

- ▶ There are a series of other pembrolizumab trials using this anti-PD-1 antibody. The randomized phase 3, KEYNOTE-040 trial is a confirmatory trial. This was actually required by the FDA as part of its approval. This is comparing pembrolizumab versus standard systemic therapy with methotrexate, docetaxel, or cetuximab in patients with recurrent metastatic squamous cell carcinoma of the head and neck who have progressed within 6 months of cisplatin therapy.

The KEYNOTE-048 trial is combining in first-line recurrent metastatic disease single-agent pembrolizumab or pembrolizumab combined with platinum in 5-FU chemotherapy or compared to the extreme regimen of cetuximab plus platinum/5-FU in first-line recurrent metastatic disease, and that's currently recruiting.

(cont'd on next page)

Other Pembrolizumab Trials

- Phase 3 KEYNOTE-040 trial (confirmatory trial to KEYNOTE-012):
 - Pembrolizumab or standard treatment with methotrexate, docetaxel, or cetuximab in patients with SCCHN
 - Study ongoing, not recruiting participants*
- Phase 3 KEYNOTE-048 trial:
 - Pembrolizumab single agent, or combined with standard treatment (platinum + 5-FU), or standard treatment alone (cetuximab + platinum + 5-FU) in the first-line treatment of recurrent/metastatic SCCHN
 - Currently recruiting participants*
- Phase 2 KEYNOTE-055 trial:
 - Pembrolizumab after progression on platinum and cetuximab in R/M HNSCC
 - Preliminary results presented at ASCO 2016
 - ORR 17-18%; OS 8 months; manageable safety profile

*As of October 2016.

5-FU, 5-fluorouracil; M, metastatic; ORR, objective response rate; OS, overall survival; R, recurrent; SCCHN, squamous cell cancer of the head and neck.

Merck Sharp & Dohme Corp, NCT02252042; NCT02358031; NCT02255097; Baumert et al, *J Clin Oncol*. 2016;34: abstract 6011.

AXIS
Medical Education

(cont'd from previous page)

The KEYNOTE-055 trial is a single-arm phase 2 trial using pembrolizumab after progression on platinum and cetuximab in recurrent metastatic head and neck cancer patients. Preliminary results were presented at ASCO 2016 with a similar overall response rate of 17% to 18%, as shown in the KEYNOTE-012 trial.

CheckMate-141 Study Design: Phase 3 Trial of Nivolumab in Recurrent SCCHN

Key eligibility criteria

- R/M SCCHN of the oral cavity, oropharynx, larynx, or hypopharynx
- ECOG PS 0-1
- Not amenable to curative therapy
- Progression ≤ 6 mo of last dose of platinum-based therapy
- Documentation of p16 for HPV status
- No active CNS metastases
- Stratified by prior cetuximab treatment

2:1

R

Nivolumab
3 mg/kg IV every 2 wk

Investigator's choice

- Methotrexate 40 mg/m² IV weekly
- Docetaxel 30 mg/m² IV weekly
- Cetuximab 400 mg/m² IV once, then 250 mg/m² weekly

Randomized
360/360

Primary endpoint

- OS

Other endpoints

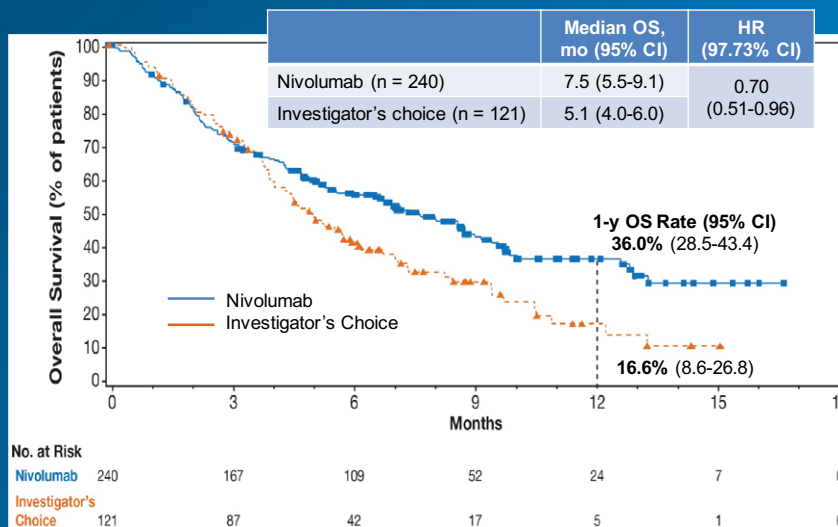
- PFS
- ORR
- Safety
- DOR
- Biomarkers
- QOL

DOR, duration of response; IV, intravenous; ORR, objective response rate; PFS, progression-free survival; Q2W, every 2 weeks; QOL, quality of life; R, randomized; SCCHN, squamous cell cancer of the head and neck. NCT02105636; Ferris et al, *J Clin Oncol*. 2016;34: abstract 6009.

AXIS
Medical Education

► The CheckMate-141 study used a different anti-PD-1 antibody. This is called nivolumab. This was the first positive randomized phase 3 trial in head and neck cancer. This was a study in recurrent metastatic cancers of the head and neck that had progressed within 6 months of cisplatin therapy, and it's stratified by prior cetuximab therapy. Patients on the CheckMate-141 study were randomized 2:1 in favor of nivolumab at a dose of 3 mg/kg every 2 weeks. The primary endpoint was overall survival, and 360 patients were randomized; 240 to nivolumab, 121 to the investigator's choice of either methotrexate, docetaxel, or cetuximab.

Overall Survival



Ferris et al. *J Clin Oncol*. 2016;34: abstract 6009.

- The overall survival, as the primary endpoint, was doubled at 1 year in patients treated with nivolumab. They had a survival of 36% at 1 year versus 16.6% with the investigator's choice of either methotrexate, docetaxel, or cetuximab.

Treatment-Related Adverse Events in ≥10% of Patients^a

Adverse Event	Nivolumab (N = 236)		Investigator's Choice (N = 111)	
	Any Grade n (%)	Grade 3/4 n (%)	Any Grade n (%)	Grade 3/4 n (%)
Any ^a	139 (58.9)	31 (13.1)	86 (77.5)	39 (35.1)
Fatigue	33 (14.0)	5 (2.1)	19 (17.1)	3 (2.7)
Nausea	20 (8.5)	0	23 (20.7)	1 (0.9)
Diarrhea	16 (6.8)	0	15 (13.5)	2 (1.8)
Anemia	12 (5.1)	3 (1.3)	18 (16.2)	5 (4.5)
Asthenia	10 (4.2)	1 (0.4)	16 (14.4)	2 (1.8)
Mucosal inflammation	3 (1.3)	0	14 (12.6)	2 (1.8)
Alopecia	0	0	14 (12.6)	3 (2.7)

^a One grade 5 event (hypercalcemia) in the nivolumab arm and one grade 5 event (lung infection) in the investigator's choice arm were reported. A second death occurred in the nivolumab arm subsequent to grade 3 pneumonitis.

Ferris et al. *J Clin Oncol*. 2016;34: abstract 6009.

- Interestingly and very importantly, nivolumab was associated with grade 3/4 adverse events at only one-third the rate of the investigator's choice chemotherapy. There was a 13% rate of these grade 3/4 adverse events, as opposed to 35% with the investigator's choice systemic therapy, demonstrating tolerability and improved quality of life in these patients.

Treatment-Related Select Adverse Events^a

Adverse Event	Nivolumab (N = 236)		Investigator's Choice (N = 111)	
	Any Grade n (%)	Grade 3/4 n (%)	Any Grade n (%)	Grade 3/4 n (%)
Skin	37 (15.7)	0	14 (12.6)	2 (1.8)
Endocrine	18 (7.6)	1 (0.4)	1 (0.9)	0
Gastrointestinal	16 (6.8)	0	16 (14.4)	2 (1.8)
Hepatic	5 (2.1)	2 (0.8)	4 (3.6)	1 (0.9)
Pulmonary	5 (2.1)	2 (0.8)	1 (0.9)	0
Hypersensitivity/Infusion reaction	3 (1.3)	0	2 (1.8)	1 (0.9)
Renal	1 (0.4)	0	2 (1.8)	1 (0.9)

^a AEs with potential immunologic etiology that require frequent monitoring/intervention.

AXIS
Medical Education

Ferris et al. *J Clin Oncol*. 2016;34: abstract 6009.

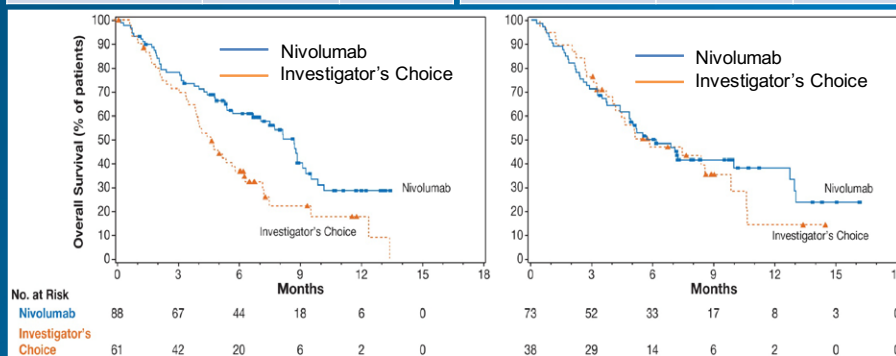
Overall Survival by PD-L1 Expression

PD-L1 Expression ≥1%

Treatment Arm	Median OS, mo (95% CI)	HR (95% CI)
Nivolumab (n = 88)	8.7 (5.7-9.1)	0.55 (0.36-0.83)
Investigator's choice (n = 61)	4.6 (3.8-5.8)	

PD-L1 Expression <1%

Treatment Arm	Median OS, mo (95% CI)	HR (95% CI)
Nivolumab (n = 73)	5.7 (4.4-12.7)	0.89 (0.54-1.45)
Investigator's choice (n = 38)	5.8 (4.0-9.8)	

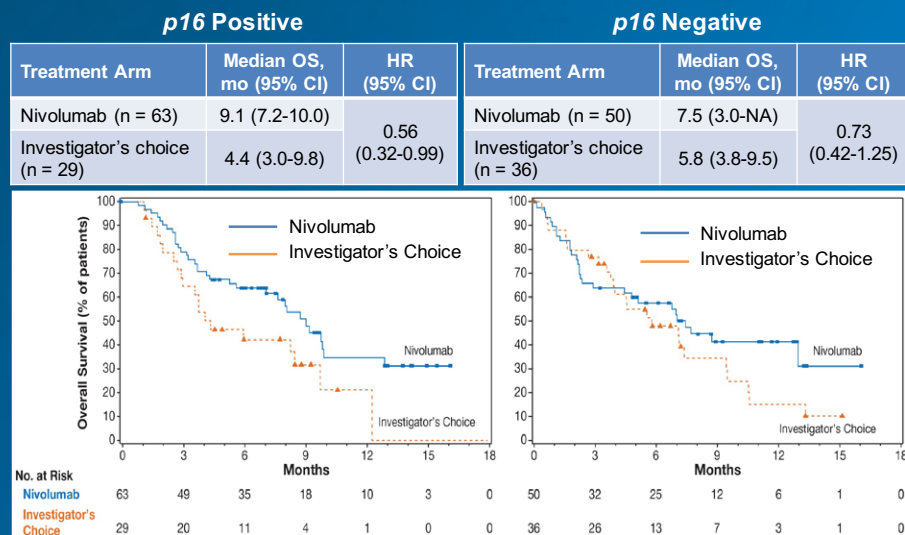


OS, overall survival; PD-L1, programmed cell death protein ligand 1.
Ferris et al. *J Clin Oncol*. 2016;34: abstract 6009.

AXIS
Medical Education

Interestingly, looking at overall survival by PD-L1 expression, the ligand for PD-1, patients who were PD-L1 positive had an improved hazard ratio and overall survival versus those who were PD-L1 negative. Although the hazard ratio favors nivolumab in these patients, the confidence interval crosses 1, and so further data will be necessary to determine the role in PD-L1 negative patients. There were some complete and partial responders in those that were PD-L1 negative, so there's clearly efficacy. And yet, we need to determine the best treatment selection for patients who are PD-L1 negative. Clearly, the PD-L1 positives had a more likelihood of benefit.

Overall Survival by p16 Status



OS, overall survival.
Ferris et al. *J Clin Oncol*. 2016;34: abstract 6009.

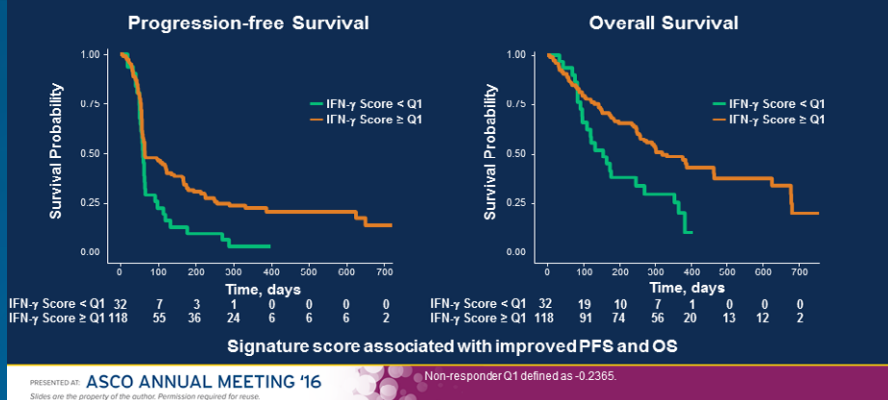
AXIS
Medical Education

- Segregating overall survival from the CheckMate 141 study by HPV status using p16 as the surrogate biomarker, patients who were p16 positive had an early separation of the curves and appeared to fare better with a hazard ratio of 0.56 versus the rest of the trial, which the hazard ratio was 0.73. In patients who were p16 negative, they did about as well as those on the rest of the trial. So nivolumab was effective in HPV-negative patients but appears to be more prominently active in the HPV-positive patients.

Progression-Free Survival and Overall Survival by IFN-γ 6-Gene Signature Score

Progression-Free Survival and Overall Survival by IFN-γ 6-gene Signature Score

L. Chow, June 6, 2016



IFN-γ, interferon gamma; OS, overall survival; PFS, progression-free survival.
Chow et al. *J Clin Oncol*. 2016;34: abstract 6010.

AXIS
Medical Education

- In the search for gene signatures to select patients most likely to benefit, data were presented at ASCO 2016 demonstrating that an interferon inflammatory gene signature could help select patients more likely to benefit. Combining the interferon gene signature with PD-L1 expression may be a combination biomarker for selecting those and enriching responders who can benefit best from these anti-PD-1 therapies.

Nivolumab FDA Approval

- **November 2016:** FDA approved nivolumab for the treatment of patients with recurrent or metastatic SCCHN with disease progression on or after a platinum-based therapy

- ▶ In November of 2016, the FDA granted full approval to nivolumab for the patients with recurrent metastatic head and neck cancer with disease progression on or after platinum-based therapy.

FDA, US Food and Drug Administration.
FDA News Release, 2016.

AXIS
Medical Education

Durvalumab (MEDI4736, Anti-PD-L1) Plus Anti-CTLA-4 Trials in SCCHN

- ▶ Not only are anti-PD-1 therapies being used, but the ligand blockade is also being tested. Durvalumab is an anti-PD-L1 antibody, and it's being used as a monotherapy in the phase 2 HAWK trial or the phase 2 CONDOR trial. These trials have completed accrual. And combinations of durvalumab targeting PD-L1 with anti-CTLA-4 using tremelimumab are now open and accruing. The CONDOR trial had a combination of CTLA-4 with PD-L1 targeting. But now the randomized phase 3 EAGLE trial and KESTREL trial in first-line or second-line recurrent metastatic head and neck cancers are open and accruing and will give us the first data on combination checkpoint inhibition against PD-L1 and CTLA-4.

	Setting	Regimen	PD-L1 Status		Rationale
Phase 2 HAWK	2L SCCHN post-plat in R/M setting	MEDI4736 mono	PD-L1+ N = 112		<ul style="list-style-type: none"> • Accelerated approval of the monotherapy in PD-L1+ Zandberg
Phase 2 CONDOR	2L SCCHN post-plat in R/M setting	MEDI4736 + tremelimumab	PD-L1- n = 120		<ul style="list-style-type: none"> • Accelerated approval of the combination in PD-L1- • Establishes individual component contribution to combination in PD-L1- Siu
		MEDI4736 mono	PD-L1- n = 60^		
		Tremelimumab mono	PD-L1- n = 60^		
Phase 3 EAGLE and KESTREL	2L SCCHN post-plat 1L pts who progressed ≤6 mo of multimodal tx w/pt in the locally advanced setting	MEDI4736 + tremelimumab	PD-L1 + n = 100	PD-L1- n = 140	<ul style="list-style-type: none"> • Confirmatory trial • Combination approval in all-comers Ferris and Licitra
		MEDI4736 mono	PD-L1 + n = 100	PD-L1- n = adaptive 140	
		SOC	PD-L1 + n = 100	PD-L1- n = 140	

CTLA-4, cytotoxic T-lymphocyte-associated protein 4; PD-L1, programmed cell death protein ligand 1; plat, platinum; R/M, relapsed/metastatic; SCCHN, squamous cell carcinoma of the head and neck; SOC, standard of care.
AstraZeneca, NCT02207530, NCT02319044, NCT02369874, NCT02551159.

AXIS
Medical Education

Avelumab: JAVELIN Solid Tumor

- Anti-PD-L1 agent
- Phase 1 JAVELIN Solid Tumor trial
- Patients with metastatic or locally advanced solid tumors, including SCCHN
- Currently recruiting participants (as of October 2016)

PD-L1, programmed cell death protein ligand 1; SCCHN, squamous cell carcinoma of the head and neck.
EMD Serono, NCT01772004.

AXIS
Medical Education

▶ Another anti-PD-L1 agent called avelumab is being tested. This has moved from the recurrent metastatic trial into the locally advanced trial. These patients have locally advanced solid tumors. The JAVELIN Solid Tumor trial has some initial cohorts with head and neck cancer demonstrating activity and is being moved into the locally advanced setting.

Cetuximab/IMRT With Ipilimumab in High-Risk Locally Advanced p16 +/- (HPV+) OPSCC: Phase 1b

Stage III/IVA OPSCC
(HPV+ smokers,
≥N2b)
p16 IHC
Tumor/
Blood collection

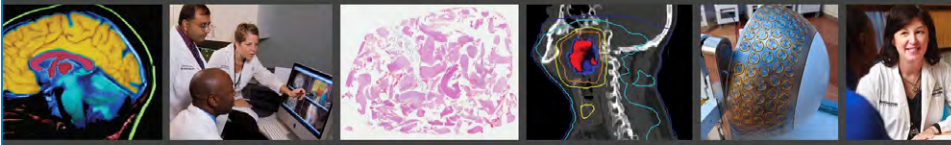
Cetuximab/Radiation therapy plus ipilimumab
IMRT 70 Gy in 6.5 wk,
cetuximab weekly at 250 mg/m² during
radiation,^a
ipilimumab 1 mg/kg 1 day, starting week 5

Accrual: 18

^a After loading dose of 400 mg/m² on cycle 1, day 1 ipilimumab will be continued at indicated dose for additional 2 cycles.
HPV, human papillomavirus; IHC, immunohistochemistry; IMRT, intensity modulated radiation therapy;
OPSCC, oropharyngeal squamous cell carcinoma.
NCT01860430; PI – Ferris.

AXIS
Medical Education

▶ We also can combine anti-CTLA-4 or other checkpoints with cetuximab radiation in the locally advanced setting. As we discussed, cetuximab radiation is an effective and FDA approved regimen. So, combining anti-CTLA-4 ipilimumab with cetuximab radiation was completed in a phase 1 trial. This was reported at ESMO of 2016 demonstrating safety and tolerability using ipilimumab at a dose of 1 mg/kg with overlap of the final 3 weeks with cetuximab radiation.



RTOG 3504

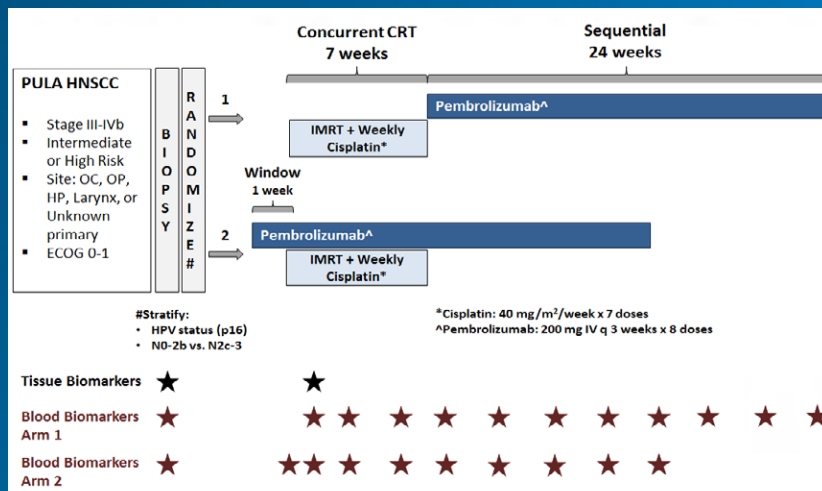
Randomized Phase III Trial of Cisplatin-Based Chemoradiotherapy (CRT) +/- Nivolumab (Anti-PD-1) in Patients with Intermediate and High-Risk Locally Advanced Head and Neck Squamous Cell Carcinoma (with Phase I Lead In)

Maura Gillison, MD, PhD, Co-Principal Investigator
Robert Ferris, MD, PhD, Co-Principal Investigator

NCT02764593.

▶ Another trial in locally advanced disease combining a checkpoint antibody now nivolumab, the anti-PD-1 antibody, is the RTOG 3504 trial. This is a randomized phase 3 trial of cisplatin-based weekly chemoradiation with or without anti-PD-1 nivolumab for intermediate- and high-risk locally advanced head and neck cancers. This is in the phase 1 lead in and will be expanded immediately to a phase 3 trial in both high-risk HPV-negative as well as intermediate-risk HPV-positive patients.

UPCI 15-132 – Sequential Versus Concomitant Pembrolizumab Plus CRT



Accrual = 7/44.
ECOG, Eastern Cooperative Oncology Group; CRT, chemo-radiation therapy; HP, hypopharynx; HPV, human papillomavirus;
IMRT, intensity-modulated radiation therapy; OC, oral cavity; OP, oropharynx.
NCT02777385; PIs Ferris and Bauman.

▶ At the University of Pittsburgh and in a multi-site trial, we are testing the sequential versus concomitant use of anti-PD-1 pembrolizumab. This trial is accruing rapidly to combine anti-PD-1 pembrolizumab in a concomitant phase or in a randomized fashion in a sequential phase to demonstrate whether oncologic efficacy or biomarkers differ when the anti-PD-1 is given in these two different regimens.

HN003 - Phase 1 & Expansion Cohort Study of Adjuvant Cisplatin-IMRT & Pembrolizumab in High-Risk, HPV-Negative HNSCC

Dose Level 3
(Starting Dose)
N = 12


Postoperative,
high-risk PULA
HNSCC

- Pathologically high risk, stage III-IV oral cavity, hypopharynx, or larynx or p16(-) oropharynx
 - + margin
 - ECE
- M0
- Zubrod 0-1

Tumor Biomarkers ★

Blood Biomarkers ★ ★ ★ ★ ★ ★ ★

Adjuvant CRT 6 weeks Maintenance 15 weeks LTFU: PFS



^Cisplatin: 40 mg/m²/week x 6 doses

*Pembrolizumab, 200 mg IV q 3 weeks x 8 doses:
Week -1 (loading dose), Week 3, 6, 9, 12, 15, 18, 21, 24

CTEP Approved Design December 2015
Dose finding cohort: 12
Dose Expansion Cohort: 20

CRT, chemo-radiation therapy; HNSCC, head and neck squamous cell carcinoma; HPV, human papillomavirus; IMRT, intensity-modulated radiation therapy; LTFU, long-term follow-up; PFS, progression-free survival.
NCT02775812; PI: Julie Bauman.

AXIS
Medical Education

► Similarly, in the postoperative setting, the Radiation Therapy Oncology Group head and neck committee in HN003 has launched a phase 1 and expansion cohort study of adjuvant high-risk resected patients who would traditionally receive cisplatin radiation but now with the addition of pembrolizumab anti-PD-1. So, these are high-risk HPV-negative head and neck cancer patients who undergo surgery, are found to have high-risk features such as positive margins and extracapsular spread. They're candidates for weekly cisplatin chemoradiation, and they'll be given adjuvant pembrolizumab in combination with the chemoradiation and then a maintenance of 15 weeks of the pembrolizumab after the chemoradiation. This is CTEP approved and is now open and accruing.

AXIS

Practical Application Cases: Applying the Use of Emerging Therapies in SCCHN to Clinical Practice

► Now we'll discuss practical application cases: applying the use of the emerging therapies in head and neck cancer to clinical practice.

Case 2

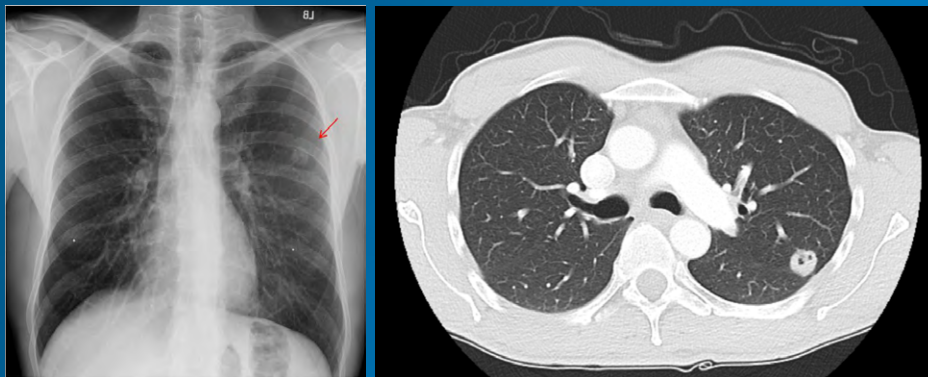
- 49-year-old man, 30 pk-year smoker, with T2N2c p16+ HPV-associated SCC of the base of tongue treated with RT + 3 cycles bolus cisplatin
- CR by PET and CT neck on 3 month post-treatment imaging
- Followed with CT scans every 3 months

CT, computed tomography; CR, complete response; HPV, human papillomavirus; PET, positron emission tomography; RT, radiation therapy; SCC, squamous cell carcinoma.

AXIS
Medical Education

- ▶ This is a 49-year-old man, a 30-pack-year smoker with an advanced HPV-positive cancer at baseline staged T2N2c of the base of the tongue. He's treated with radiation therapy with bolus cisplatin 100 mg/m² every 21 days. He has a complete response by PET and CT at 3 months on posttreatment imaging. He's followed with CT scans every 3 months for the first year.

Case 2 (cont): 6 months post-treatment CT showed a suspicious lung nodule



CT, computed tomography.

AXIS
Medical Education

- ▶ At 6 months, a suspicious left lung nodule is found on the posttreatment scan, as shown on the chest radiograph and CT scan.

Case 2 (cont)

- Biopsy confirmed *p16+* HPV+ SCC
- No other sites of disease on PET-CT

- ▶ The biopsy confirms that this is *p16* of HPV-positive metastatic squamous cell carcinoma. There are no other sites of disease, so low volume distant metastasis.

CT, computed tomography; HPV, human papillomavirus; PET, positron emission tomography; SCC, squamous cell carcinoma.

AXIS
Medical Education

Case 2 Question 1: How would you treat this patient?

- a) Observation
- b) Palliative chemotherapy
- c) Wedge resection/local therapy
- d) Anti-PD-1 immunotherapy

- ▶ We have different options for how to treat this patient. Either observation, palliative chemotherapy, or wedge resection and local therapy, or finally—now with the FDA approvals of nivolumab and pembrolizumab—anti-PD-1 immunotherapy.

PD-1, programmed cell death protein 1.

AXIS
Medical Education

Key Takeaways

- HPV defines 2 separate groups of SCCHN with different clinical needs, improved survival (HPV-) versus de-intensified therapy (HPV+)
- Transoral robotic surgery is effective, feasible, and safe – trials underway
- Immunotherapy of SCCHN is effective and being integrated into all lines and phases of therapy

HPV, human papillomavirus; SCCHN, squamous cell carcinoma of the head and neck.

AXIS
Medical Education

► So the key take-aways are that HPV defines 2 separate groups of head and neck cancers with different clinical needs. Improved survival for the HPV-negative group versus de-intensified therapy for the HPV-positive group. We now have seen that transoral robotic surgery, which was FDA approved for head and neck cancer in 2009, is effective; it's feasible and safe. But trials are underway to assess whether it can be a tool for de-intensified adjuvant radiotherapy. We now have seen that immunotherapy of head and neck cancer is effective; it's now being integrated into all lines and phases of therapy.

AXIS

Thank You

► Thank you.

REFERENCES

- Adkins D, Ley J, Wildes T, et al. A phase 1 trial of pazopanib added to cetuximab in patients with incurable head and neck squamous cell carcinoma (HNSCC). Presented at: 2016 Multidisciplinary Head and Neck Cancer Symposium; February 18-20, 2016; Scottsdale, Arizona.
- Ang KK, Harris J, Wheeler R, et al. Human papillomavirus and survival of patients with oropharyngeal cancer. *N Engl J Med*. 2010;363:24-35.
- AstraZeneca. NCT02207530. A phase II, multi-center, single-arm, global study of MEDI4736 monotherapy in patients with recurrent or metastatic squamous cell carcinoma of the head and neck (SCCHN). <https://clinicaltrials.gov/ct2/show?term=medi4736&cond=head+and+neck+cancer&phase=1&rank=3>. Accessed November 7, 2016.
- AstraZeneca. NCT02319044. A phase II, randomized, open-label, multi-center, global study of MEDI4736 monotherapy, tremelimumab monotherapy, and MEDI4736 in combination with tremelimumab in patients with recurrent or metastatic squamous cell carcinoma of the head and neck (SCCHN). <https://clinicaltrials.gov/ct2/show?term=medi4736&cond=head+and+neck+cancer&phase=1&rank=4>. Accessed November 7, 2016.
- AstraZeneca. NCT02369874. Study of MEDI4736 monotherapy and in combination with tremelimumab versus standard of care therapy in patients with head and neck cancer. <https://clinicaltrials.gov/ct2/show/NCT02369874?term=NCT02369874&rank=1>. Accessed November 7, 2016.
- AstraZeneca. NCT02551159. Phase III open label study of MEDI 4736 with/without tremelimumab versus standard of care (SOC) in recurrent/metastatic head and neck cancer (KESTREL). <https://clinicaltrials.gov/ct2/show/NCT02551159>. Accessed November 7, 2016.
- AstraZeneca Press Release. December 18, 2015. Durvalumab ATLANTIC trial supports clinical activity and AstraZeneca's overall immuno-oncology strategy. <https://www.astrazeneca.com/media-centre/press-releases/2015/Durvalumab-ATLANTIC-trial-supports-clinical-activity-and-AstraZenecas-overall-immuno-oncology-strategy.html>. Accessed November 7, 2016.
- Baumi J, Seiwert TY, Pfister DG, et al. Preliminary results from KEYNOTE-055: Pembrolizumab after platinum and cetuximab failure in head and neck squamous cell carcinoma (HNSCC). *J Clin Oncol*. 2016;34: abstract 6011.
- Bonner JA, Harari PM, Giralt J, et al. Radiotherapy plus cetuximab for squamous-cell carcinoma of the head and neck. *N Engl J Med*. 2006;354:567-578.
- Bristol-Myers Squibb. NCT02105636. An open label, randomized phase 3 clinical trial of nivolumab vs therapy of investigator's choice in recurrent or metastatic platinum-refractory squamous cell carcinoma of the head and neck (SCCHN). <https://clinicaltrials.gov/ct2/show/NCT02105636>. Accessed November 7, 2016.
- Califano J, van der Riet P, Westra W, et al. Genetic progression model for head and neck cancer: implications for field cancerization. *Cancer Res*. 1996;56:2488-2492.
- Centers for Disease Control and Prevention. Current cigarette smoking among adults—United States, 2005–2014. *Morbidity Mortal Wkly Rep*. 2015;64:1233-1240.
- Chaturvedi AK, Engels EA, Pfeiffer RM, et al. Human papillomavirus and rising oropharyngeal cancer incidence in the United States. *J Clin Oncol*. 2011;29:4294-4301.
- Chow LQ, Haddad R, Gupta S, et al. Antitumor activity of pembrolizumab in biomarker-unselected patients with recurrent and/or metastatic head and neck squamous cell carcinoma: results from the phase 1b KEYNOTE-012 expansion cohort. *J Clin Oncol*. 2016;34:3838-3845.
- Chow LQM, Mehra R, Haddad RI, et al. Biomarkers and response to pembrolizumab (pembro) in recurrent/metastatic head and neck squamous cell carcinoma (R/M HNSCC). *J Clin Oncol*. 2016;34: abstract 6010.
- Cmelak A, Li S, Marur S, et al. E1308: Reduced-dose IMRT in human papilloma virus (HPV)-associated resectable oropharyngeal squamous carcinomas (OPSCC) after clinical complete response (cCR) to induction chemotherapy (IC). *J Clin Oncol*. 2014;32: abstract LBA6006.
- Cohen EE, LaMonte SJ, Erb NL, et al. American Cancer Society head and neck cancer survivorship care guidelines. *CA Cancer J Clin*. 2016;66:203-239.
- Eastern Cooperative Oncology Group. NCT01084083. A phase II trial of induction chemotherapy followed by cetuximab (erbitux) with low dose vs. standard dose IMRT in patients with HPV-associated resectable squamous cell carcinoma of the oropharynx. <https://clinicaltrials.gov/ct2/show/NCT01084083?term=ecog+1308&rank=1>. Accessed November 7, 2016.
- Eastern Cooperative Oncology Group. NCT01898494. Phase II randomized trial of transoral surgical resection followed by low-dose or standard-dose IMRT in resectable p16+ locally advanced oropharynx cancer. <https://clinicaltrials.gov/ct2/show/NCT01898494?term=E3311&rank=1>. Accessed November 7, 2016.
- EMD Serono. NCT01772004. Avelumab in metastatic or locally advanced solid tumors (JAVELIN solid tumor). <https://clinicaltrials.gov/ct2/show/NCT01772004?term=NCT01772004&rank=1>. Accessed November 7, 2016.
- FDA News Release. March 1, 2006. FDA approves first head & neck cancer treatment in 45 years data shows treatment with erbitux extends survival. <http://www.fda.gov/NewsEvents/Newsroom/PressAnnouncements/2006/ucm108609.htm>. Accessed November 7, 2016.
- FDA News Release. November 7, 2011. FDA approved Erbitux to treat late-stage head and neck cancer. <http://www.fda.gov/NewsEvents/Newsroom/PressAnnouncements/ucm278894.htm>. Accessed November 7, 2016.
- FDA News Release. August 5, 2016. Pembrolizumab (Keytruda). <http://www.fda.gov/Drugs/InformationOnDrugs/ApprovedDrugs/ucm515627.htm>. Accessed November 15, 2016.

REFERENCES

- FDA News Release. November 10, 2016. Nivolumab for SCCHN. <http://www.fda.gov/Drugs/InformationOnDrugs/ApprovedDrugs/ucm528920.htm>. Accessed November 10, 2016.
- Ferris RL, Blumenschein GR, Fayette J, et al. Further evaluations of nivolumab (nivo) versus investigator's choice (IC) chemotherapy for recurrent or metastatic (R/M) squamous cell carcinoma of the head and neck (SCCHN): CheckMate 141. *J Clin Oncol*. 2016;34: abstract 6009.
- Ferris RL, Even C, Haddad R, et al. Phase III, randomized, open-label study of durvalumab (MEDI4736) monotherapy, or durvalumab + tremelimumab, versus standard of care (SoC), in recurrent or metastatic (R/M) squamous cell carcinoma of the head and neck (SCCHN): EAGLE. *J Immunother Cancer* 2015;3:P150.
- Forastiere A, Koch W, Trotti A, et al. Head and neck cancer. *N Engl J Med*. 2001;345:1890-1900.
- Forastiere AA, Zhang Q, Weber RS, et al. Long-term results of RTOG 91-11: a comparison of three nonsurgical treatment strategies to preserve the larynx in patients with locally advanced larynx cancer. *J Clin Oncol*. 2013;31:845-852.
- Galon J, Costes A, Sanchez-Cabo F, et al. Type, density, and location of immune cells within human colorectal tumors predict clinical outcome. *Science* 2006;313:1960-1964.
- Gutcher I, Becher B. APC-derived cytokines and T cell polarization in autoimmune inflammation. *J Clin Invest*. 2007;117:1119-1127.
- Holmes D. PI3K pathway inhibitors approach junction. *Nat Rev Drug Disc*. 2011;10:563-564.
- Keir ME, Butte MJ, Freeman GJ, Sharpe AH. PD-1 and its ligands in tolerance and immunity. *Annu Rev Immunol*. 2008;26:677-704.
- Machtay M, Moughan J, Trotti A. Factors associated with severe late toxicity after concurrent chemoradiation for locally advanced head and neck cancer: an RTOG analysis. *J Clin Oncol*. 2008;26:3582-3589.
- Melotek JM, Haraf DJ, Blair EA, et al. Final results of a randomized phase 2 trial investigating the addition of cetuximab to induction chemotherapy and accelerated or hyperfractionated chemoradiation therapy for locoregionally advanced head and neck cancer: HPV-negative subset analysis. *Radiat Oncol*. 2016;94:867.
- Mendenhall WM, Amdur RJ, Stringer SP, et al. Radiation therapy for squamous cell carcinoma of the tonsillar region: a preferred alternative to surgery? *J Clin Oncol*. 2000;18:2219-2225.
- Merck Sharp & Dohme Corp. NCT02358031. A study of pembrolizumab (MK-3475) for first line treatment of recurrent or metastatic squamous cell cancer of the head and neck (MK-3475-048/KEYNOTE-048). <https://clinicaltrials.gov/ct2/show/NCT02358031?term=NCT02358031&rank=1>. Accessed November 7, 2016.
- Merck Sharp & Dohme Corp. NCT02252042. Pembrolizumab (MK-3475) versus standard treatment for recurrent or metastatic head and neck cancer (MK-3475-040/KEYNOTE-040). <https://clinicaltrials.gov/ct2/show/NCT02252042?term=NCT02252042&rank=1>. Accessed November 7, 2016.
- Merck Sharp & Dohme Corp. NCT02255097. Study of pembrolizumab (MK-3475) in subjects with recurrent or metastatic head and neck squamous cell carcinoma (HNSCC) who have failed platinum and cetuximab. <https://clinicaltrials.gov/ct2/show/NCT02255097>. Accessed November 7, 2016.
- National Cancer Institute. NCT02775812. A phase I and expansion cohort study of adjuvant cisplatin, intensity-modulated radiotherapy, and pembrolizumab in high-risk head and neck squamous cell carcinoma (HNSCC). <https://clinicaltrials.gov/ct2/show?term=hn003&rank=3>. Accessed November 7, 2016.
- Pfister DG, Spencer S, Brizel DM, et al. NCCN Clinical Practice Guidelines in Oncology (NCCN Guidelines®) Head and Neck Cancers. Version 2.2016. © 2016 National Comprehensive Cancer Network, Inc. https://www.nccn.org/professionals/physician_gls/pdf/head-and-neck.pdf. Accessed November 7, 2016.
- Purow B. Notch inhibition as a promising new approach to cancer therapy. *Adv Exp Med Biol*. 2012;727:305-319.
- Radiation Therapy Oncology Group. NCT01302834. Radiation therapy with cisplatin or cetuximab in treating patients with oropharyngeal cancer. <https://clinicaltrials.gov/ct2/show/NCT01302834>. Accessed November 7, 2016.
- RTOG Foundation, Inc. NCT02764593. Randomized phase III trial of cisplatin-based chemotherapy (CRT) +/- nivolumab (anti-PD-1) in patients with intermediate and high-risk local-regionally advanced head and neck squamous cell carcinoma (with phase I lead in). <https://clinicaltrials.gov/ct2/show/NCT02764593>. Accessed November 7, 2016.
- Rosenthal DI, Harari PM, Giralk J, et al. Association of human papillomavirus and p16 status with outcomes in the IMCL-9815 phase III registration trial for patients with locoregionally advanced oropharyngeal squamous cell carcinoma of the head and neck treated with radiotherapy with or without cetuximab. *J Clin Oncol*. 2016;34:1300-1308.
- Schreiber RD, Old LJ, Smyth MJ. Cancer immunoediting: integrating immunity's roles in cancer suppression and promotion. *Science* 2011;331:1565-1570.
- Seiwert TY, Haddad RI, Gupta S, et al. Antitumor activity of the anti-PD-1 antibody pembrolizumab in biomarker-unselected patients with R/M head and neck cancer: preliminary results from the KEYNOTE-012 expansion cohort. *J Clin Oncol*. 2015;33: abstract LBA6008.

REFERENCES

- Seiwert TY, Burtneß B, Mehra R, et al. Safety and clinical activity of pembrolizumab for treatment of recurrent or metastatic squamous cell carcinoma of the head and neck (KEYNOTE-012): an open-label, multicentre, phase 1b trial. *Lancet Oncol*. 2016;17:956-965.
- Selek U, Garden AS, Morrison WH, et al. Radiation therapy for early-stage carcinoma of the oropharynx. *Int J Radiat Oncol Biol Phys*. 2004;59:743-751.
- Sharma P, Allison JP. Immune checkpoint targeting in cancer therapy: toward combination strategies with curative potential. *Cell*. 2015;161:205-214.
- Stransky N, Egloff AM, Tward AD, et al. The mutational landscape of head and neck squamous cell carcinoma. *Science*. 2011;333:1157-1160.
- The Cancer Genome Atlas Network. Comprehensive genomic characterization of head and neck squamous cell carcinomas. *Nature*. 2015;517:576-582.
- University of Pittsburgh. NCT01860430. A phase 1b trial of concurrent cetuximab (Erbix®) and intensity modulated radiotherapy (IMRT) with ipilimumab (Vervoy®) in locally advanced head and neck cancer. <https://clinicaltrials.gov/ct2/show/NCT01860430>. Accessed November 7, 2016.
- University of Pittsburgh. NCT02777385. Randomized, phase II study evaluating concurrent or sequential fixed-dose pembrolizumab in combination with cisplatin and intensity modulated radiotherapy in intermediate or high risk, previously untreated, locally advanced head and neck cancer. <https://clinicaltrials.gov/ct2/show/NCT02777385>. Accessed November 7, 2016.
- Vermorken JB, Mesia R, Rivera F, et al. Platinum-based chemotherapy plus cetuximab in head and neck cancer. *N Engl J Med*. 2008;359:1116-1127.
- Yom SS. NRG-HN002: A randomized phase II trial for patients with p16 positive, non-smoking associated, locoregionally advanced oropharyngeal cancer, NCT02254278. <https://www.nrgoncology.org/Clinical-Trials/NRG-HN002>. Accessed November 7, 2016.

About AXIS Medical Education, Inc.

AXIS Medical Education, Inc. is a full-service continuing education company that designs and implements live, web-based, and print-based educational activities for healthcare professionals. AXIS provides convenient opportunities to engage learners based on their individual learning preferences through a full spectrum of educational offerings.

The executive leadership of AXIS combines 75 years of experience in adult learning theory, curriculum design/implementation/assessment, continuing education accreditation standards, and medical meeting planning and logistics. Our team has a deep understanding of the governing guidelines overseeing the medical education industry to ensure compliant delivery of all activities.

AXIS employs an experienced team of medical and scientific experts, medical writers, project managers, meeting planners, and logistics professionals. This team is dedicated to meeting the unmet educational needs of healthcare professionals, with the goal of improving patient outcomes.

AXIS believes that partnerships are crucial in our mission to deliver timely, relevant, and high-quality medical education to healthcare professionals. To that end, AXIS partners with other organizations and accredited providers to offer added expertise and assist in expanding access to our educational interventions. AXIS also partners with numerous patient advocacy organizations to provide recommended patient education and caregiver resources in specific disease areas. AXIS finds value in these partnerships because they complement our core clinical curriculum with validated and relevant supplemental resources for busy clinicians and their patients.

The mission of AXIS is to enhance the knowledge, skills, competence, and performance of the interprofessional healthcare team to ensure patients receive quality care, resulting in improved patient outcomes. We engage healthcare professionals in fair-balanced, scientifically rigorous, expert-led certified educational activities designed to foster lifelong learning that is applicable to clinical practice and patient-centered care.

To learn more and to see our current educational offerings, visit us online at www.AXISMedEd.com.

